

Identification of Age

Presented
By

Dr/ Said Said Elshama

Professor of Forensic Medicine and Clinical Toxicology

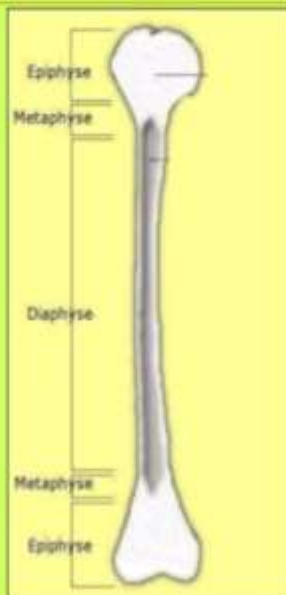
Medical Education (DHPE)

College of Medicine - Taif & Suez Canal University

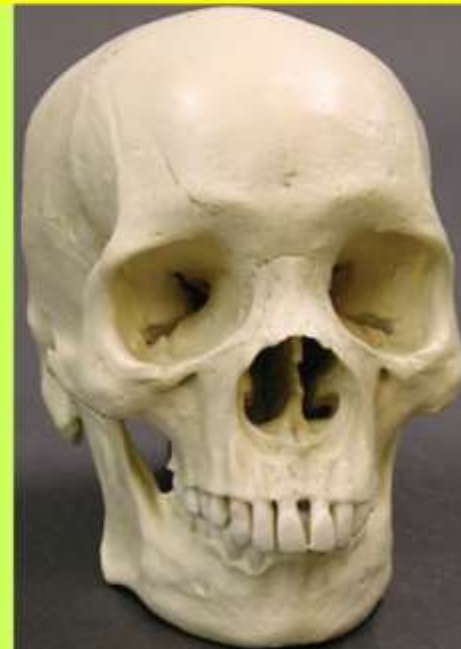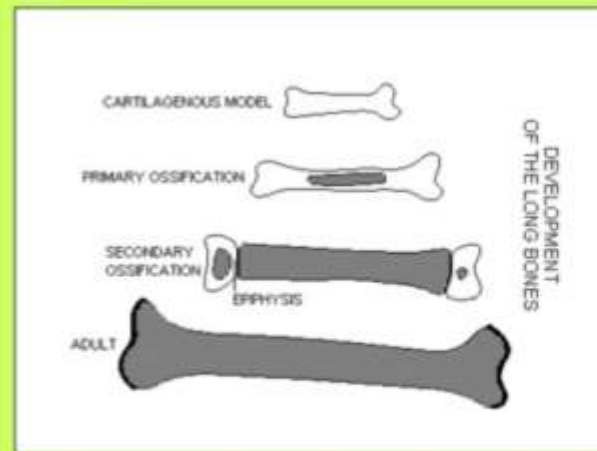How do you estimate age of any person?

Estimation of age by the following:-

- 1- Skull
- 2- Ossific Centers
- 3- Union of Epiphyses



Appearance of ossific centers after birth

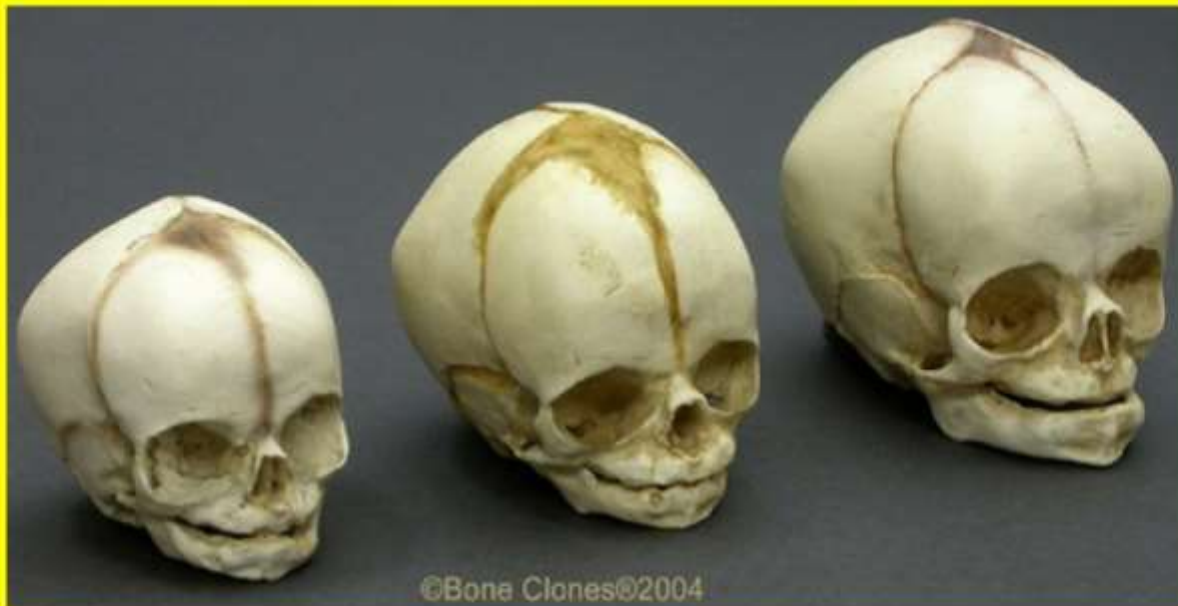

Skull

1-Dimensions:

(head circumference , Length, width)

Ex. Mature skull of infant = 13 inches, 5 inches, 4 inches



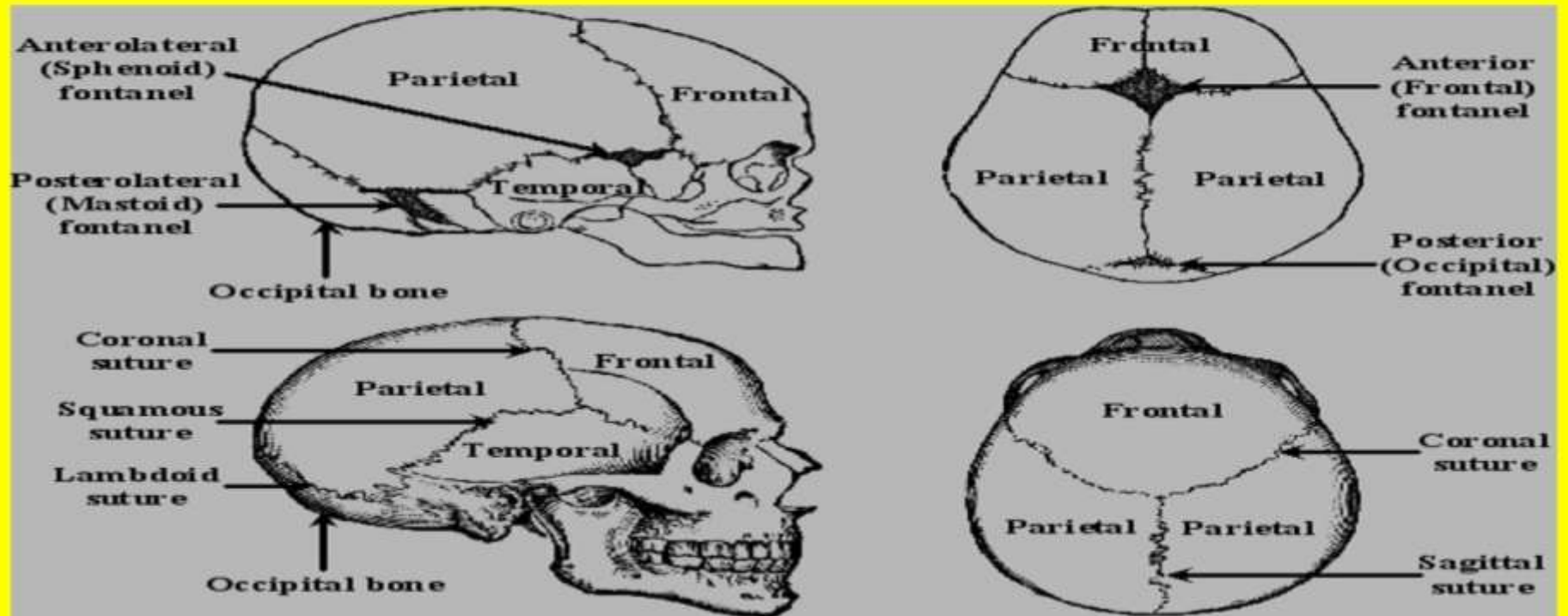
2-Fontanelles :

Closure of posterior fontanelle at full term

Closure of anterior fontanelle at (1½ - 2 years)

3-Sutures

1. Closure of Frontal suture (metopic) at 2 years
2. Basi-occipital with basisphenoid (23)
3. Closure of sagittal suture (25- 30)
4. Closure of coronal suture (40)
5. Closure of lambdoid suture (50)
6. All skull bones fusion (70)
7. Suture of temporal - parietal remains open until extreme old age



NOTE: Skulls are not to scale

Ectocranial Suture Closure

Age	Sagittal	Lambdoid	Coronal
17	0.73	0.13	0.00
19	1.15	0.45	0.31
21	1.55	0.75	0.68
23	1.92	1.03	1.04
25	2.27	1.28	1.36
27	2.58	1.49	1.64
29	2.84	1.67	1.88
31	3.06	1.80	2.07
33	3.22	1.88	2.20
35	3.32	1.90	2.27

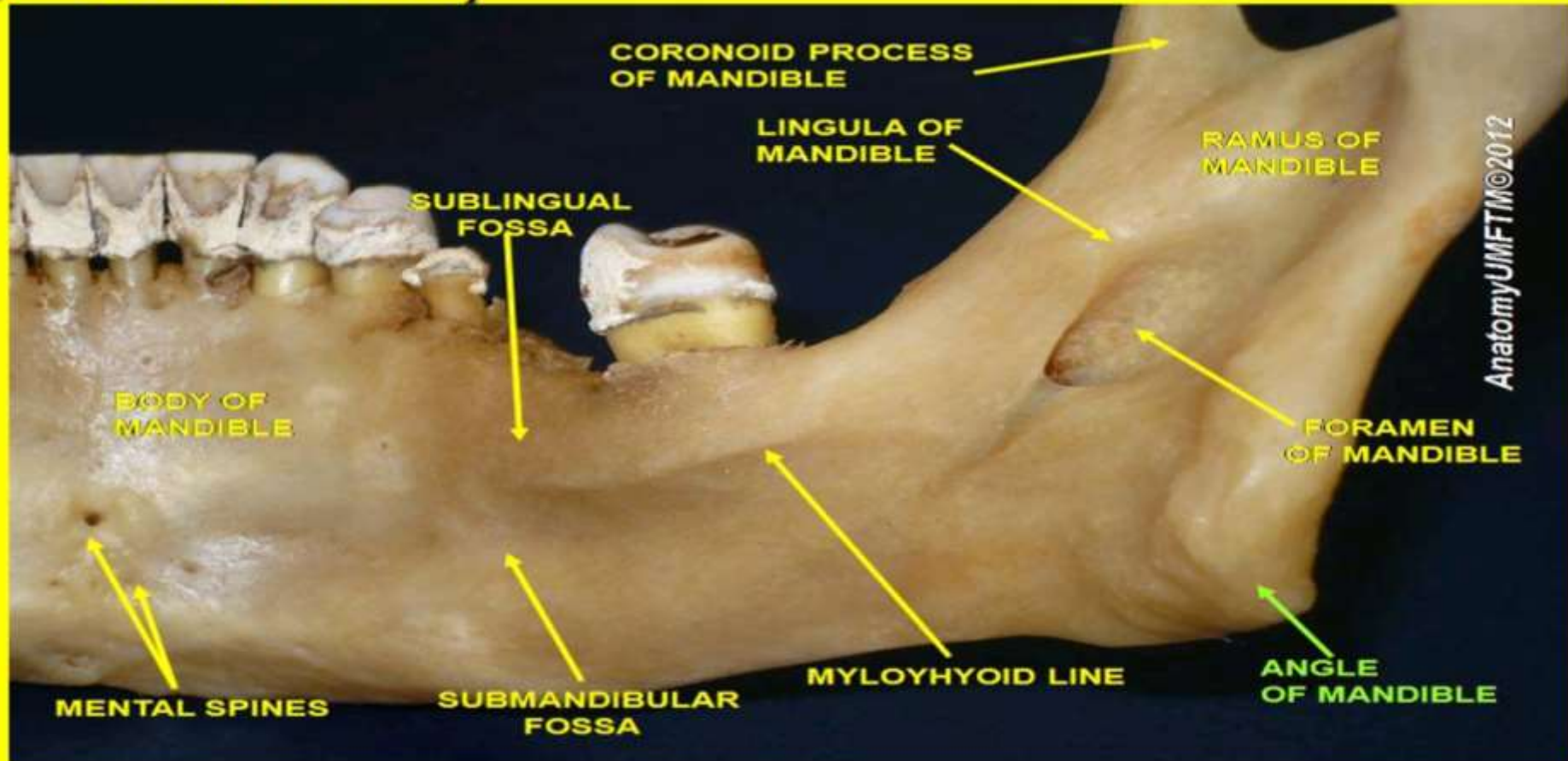
SOURCE: Modified from values in McKern and Stewart 1957:28.

NOTE: Values are the expected mean score for the degree of closure using the scale: 0 = open, 1 = $\frac{1}{4}$ closed, 2 = $\frac{2}{4}$ closed, 3 = $\frac{3}{4}$ closed, 4 = completely closed. In reality, suture closure is not a reliable indicator of age since skulls exhibit very large variability in rate of closure.

4-Mandible

Angle of mandible (between body and ramus)

1. Obtuse in infant
2. Right in middle life
3. Obtuse in senility



5-Teeth

Milk teeth

Number = 20 – start about 6 months

Milk dentition

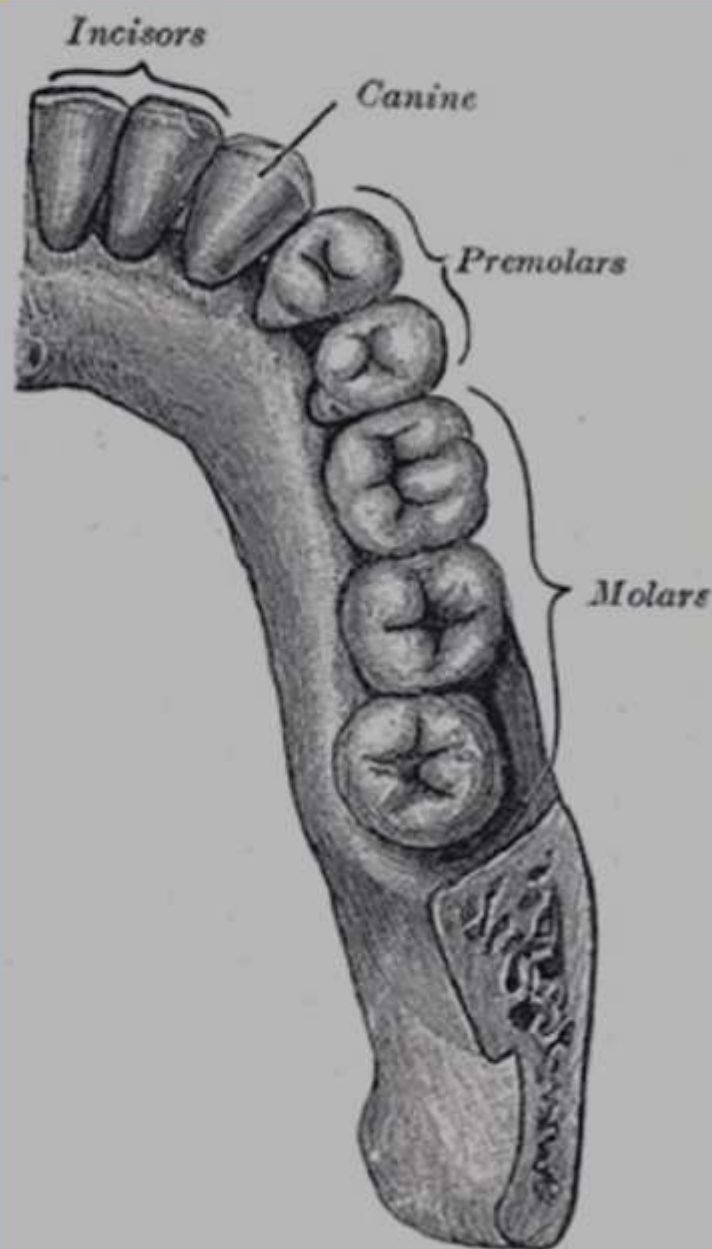
- Central incisor 6 months
- Lateral incisor 9 months
- First molar 12 months
- Canine 18 months
- Second molar 24 months

Permanent teeth

Number= 32- start about 6 years

Permanent dentition

- First molar 6 years
- Central incisor 7 years
- Lateral incisor 8 years
- First bicuspid 9 years
- Second bicuspid 10 years
- Canine 11 years
- Second molar 12 years
- Third molar (wisdom tooth) 18-25 years



Ossific Centers

Ossification center is point of starting ossification (calcification) in the cartilage.

Types of ossification centers:-

1- Primary ossification center

The first area of a bone to start ossifying.

It is found in diaphysis of long bones .

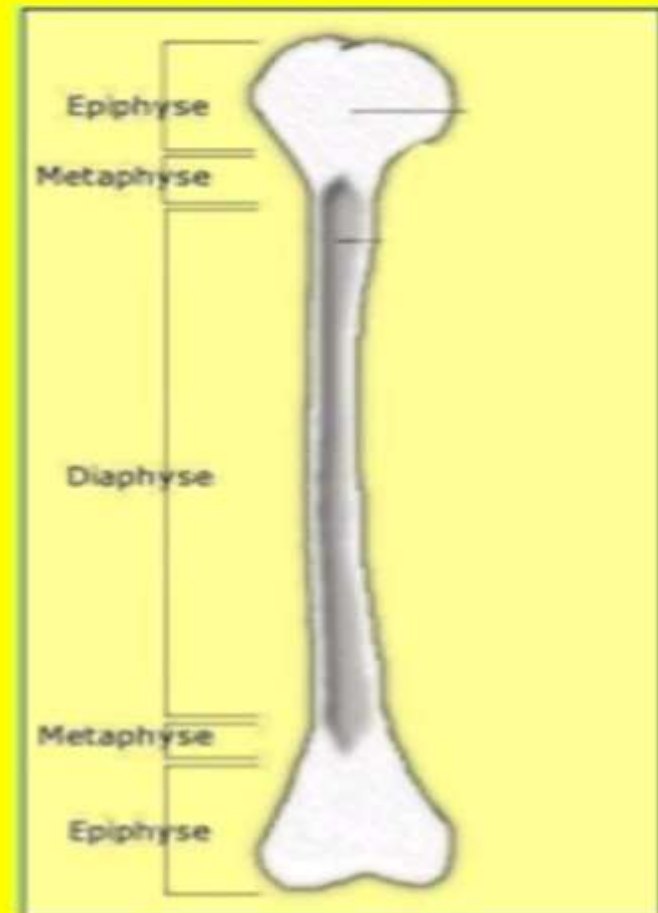
It appears during prenatal period.

2- Secondary ossification center


It appears after primary center .

It appears in the epiphysis.


It appears during the postnatal and adolescent years.




CARTILAGENOUS MODEL




PRIMARY OSSIFICATION



SECONDARY
OSSIFICATION



ADULT



Ossific Centers Appearance

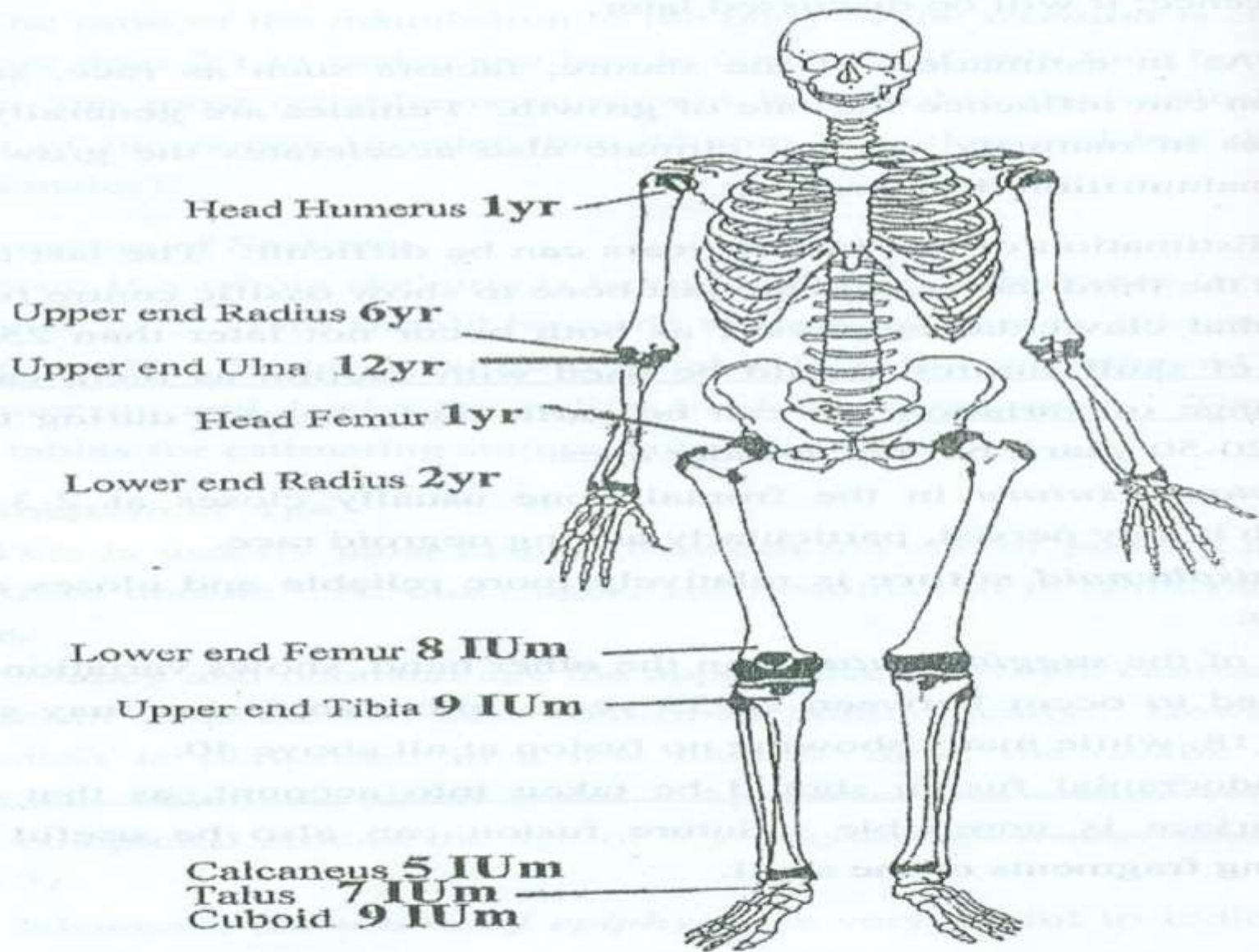
Appearance of ossific centers

During intrauterine life (Primary)

- Calcaneus centre **5th month**
- Talus centre **7th month**
- Lower end of femur **8th month**
- Cuboid and upper end of tibia **at full term**

After birth (Secondary)

- Head of humerus and femur **1st year**
- Lower end of radius **2nd year**
it attains 2/3 the breadth of the epiphysis **7 years**
- Upper end of radius **6 years**
- Upper end of ulna **12 years**

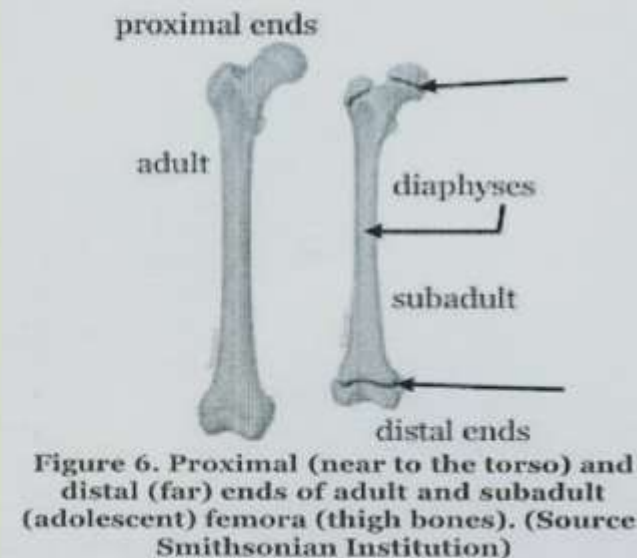
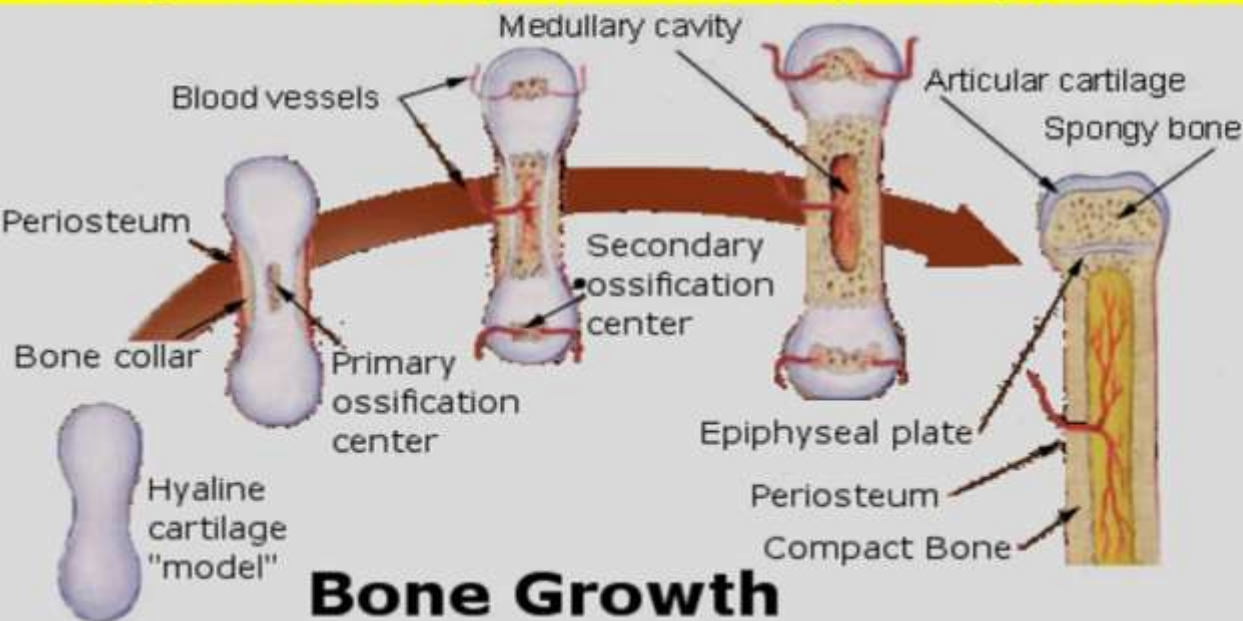


(Figure 3) Average Ages of Appearance of Ossific Centres

Union of Epiphyses

Bone growth

- **At birth**, ends of long bones are mainly cartilage (with centers of bone inside it)
- **Child grows**, shafts get longer and bone gradually replaces epiphyseal cartilage
- **Through growing years**, a layer of cartilage called the growth plate, separates each epiphysis from the bone shaft.
- **The age of a person** can be estimated by stages of union of epiphyses of bones.
- This process occurs slightly earlier in females than in males.
- The process is complete between 17 and 25 years, when normal growth stops.



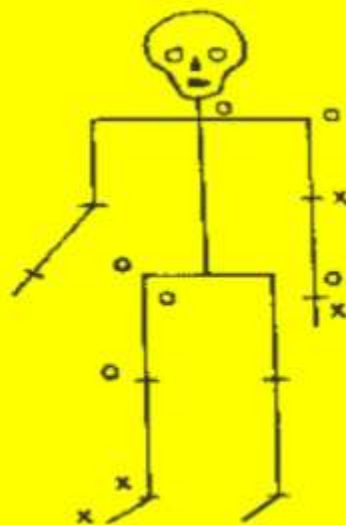
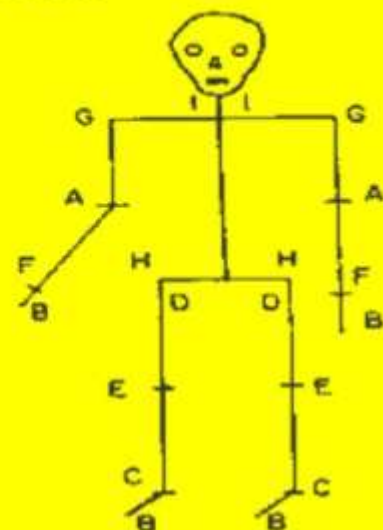
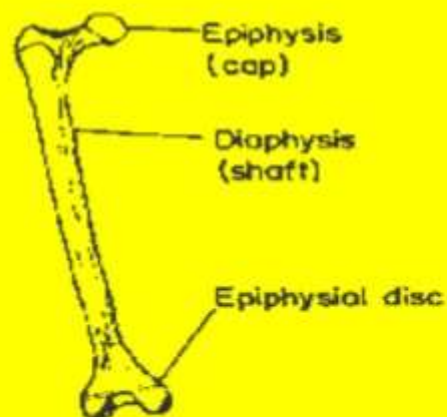
greater trochanter

lesser trochanter

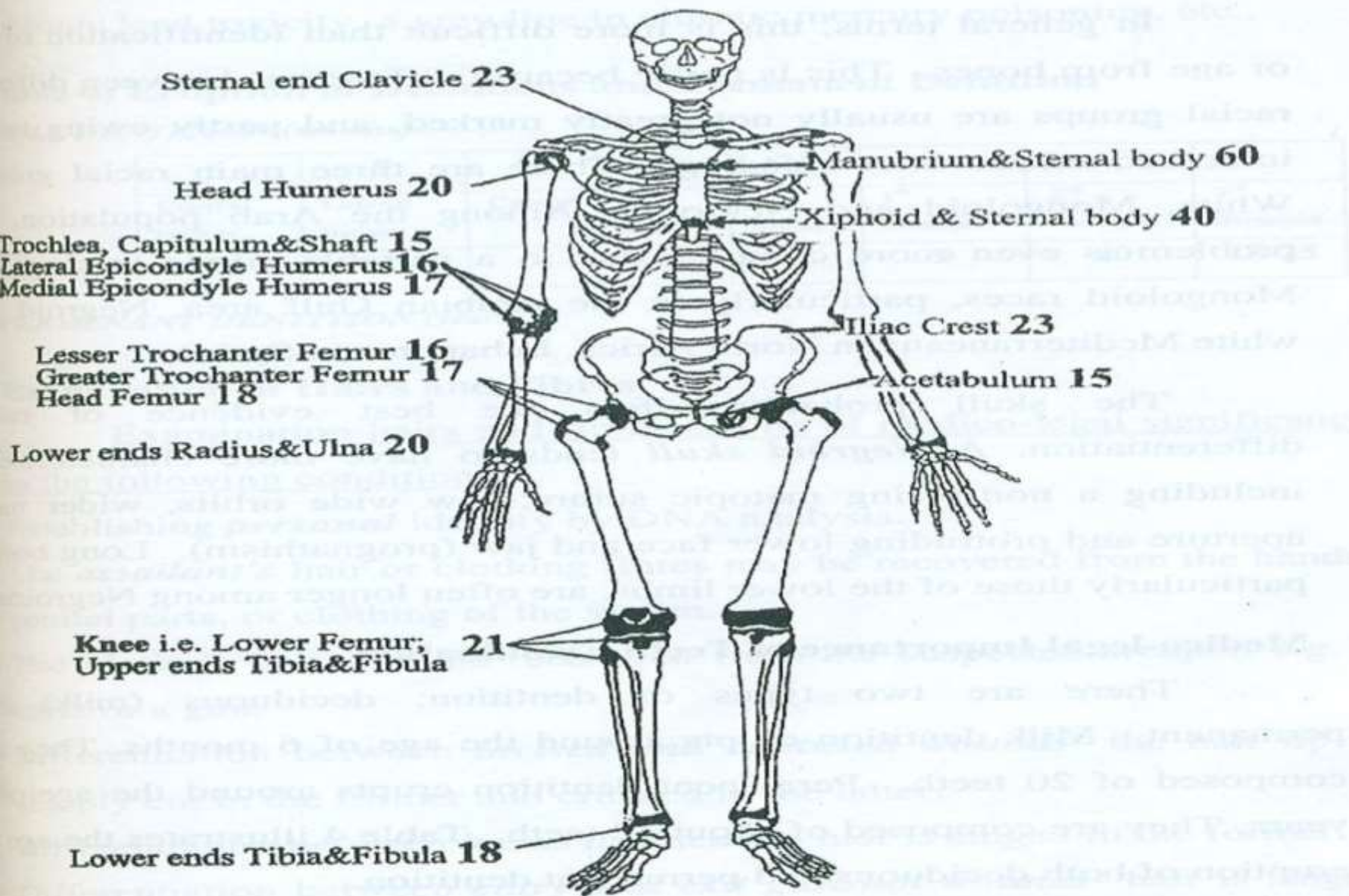
epiphyseal line

THE AGE ORDER OF COMPLETE EPIPHYSIAL UNION

A	Elbow	14 years
B	Hands and feet	15 "
C	Ankle	16 "
D	Thigh (proximal femur)	17 "
E	Knee	18 "
F	Wrist	19 "
G	Shoulder	20 "
H	Hip (crest of ilium)	21 "
I	Clavicle (proximal end)	28 "



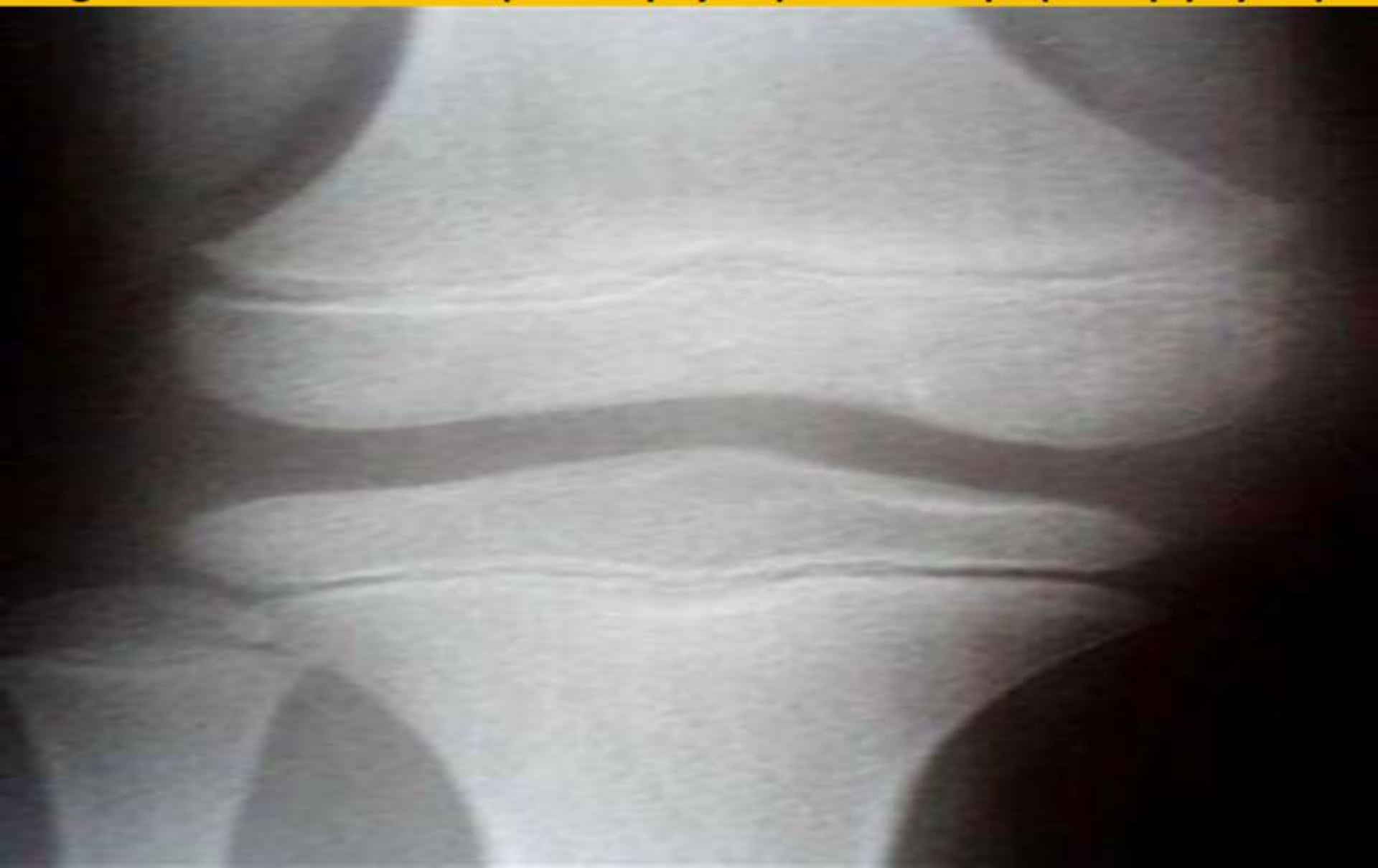The figure on the left illustrates the degree of epiphysial union in a person between 16 and 17 years of age. An 'x' indicates complete union, and an 'o' indicates non union.



(Figure 4) Average Ages of Epiphyseal Closure

Union of epiphyses	Age (years)
Lower end of humerus +trochela unites with capitulum	14
trochela unites with capitulum and fuse with shaft	15
Lateral epicondyle and medial epicondyle	16-17
Head of humerus	20 ◀
Upper end of ulna	16
Upper end of radius	17
Distal ends of ulna and radius	20 ◀
Metacarpals and phalanges	18
Lesser trochanter of femur	16
Greater trochanter of femur	17
Head of femur	18
Lower end of femur	21 ●
Lower end of tibia & fibula	18
Upper end of tibia	21 ●
Pubic ramus with ischium	6
ilium, ischium with pubic bones	15
Greater tuberosity of ischium	21 ●
Iliac crest and sternal end of clavicle	23
Greater cornu of hyoid bone +xiphoid process of sternum	40
manubrium with body of sternum	60

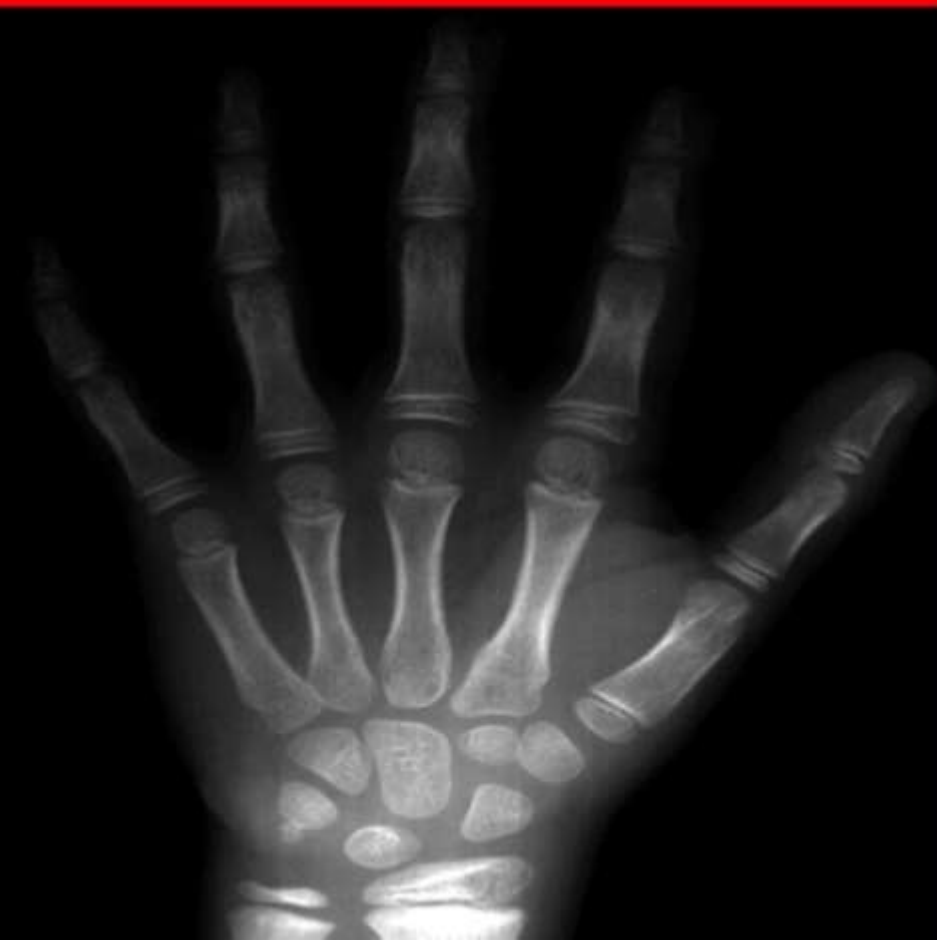This is an x-ray of a young person's knee. Notice the lines between the longer shafts of the bone (the diaphyses) and the tips (the epiphyses).



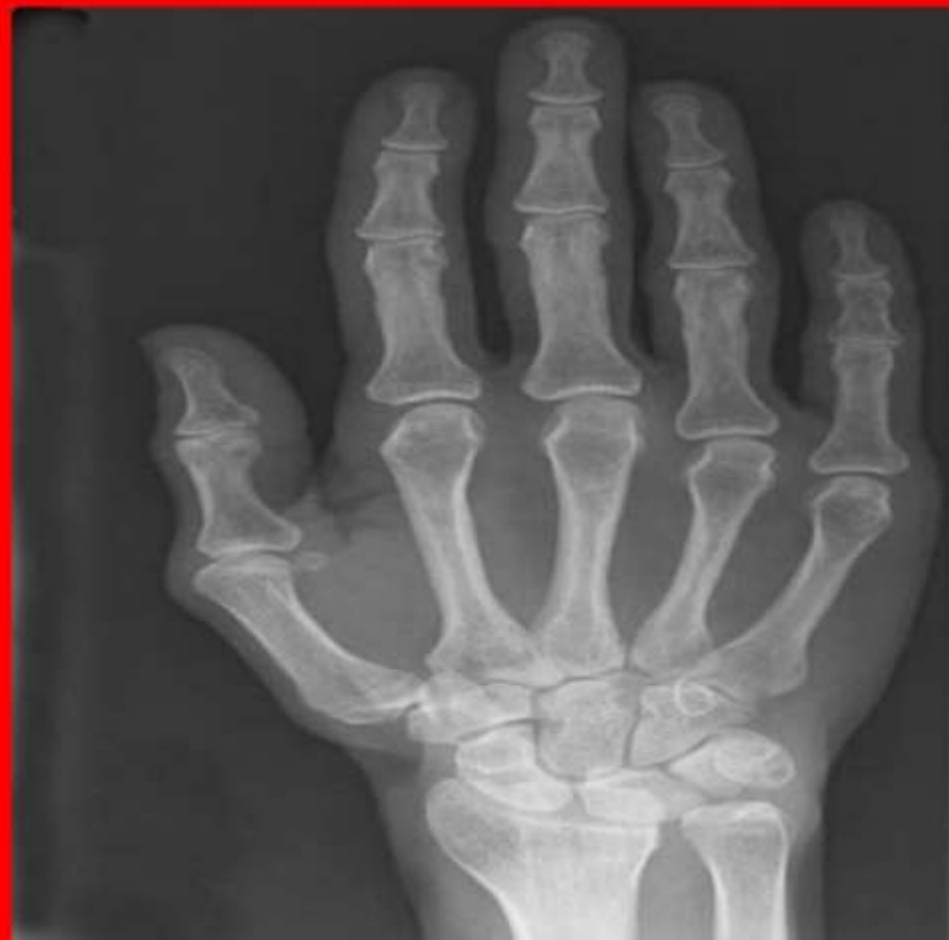1-Child's Wrist and Hand, showing the clear lines at the end (epiphysis) of the long bones. These areas, which are made of cartilage, are the epiphyseal plates.

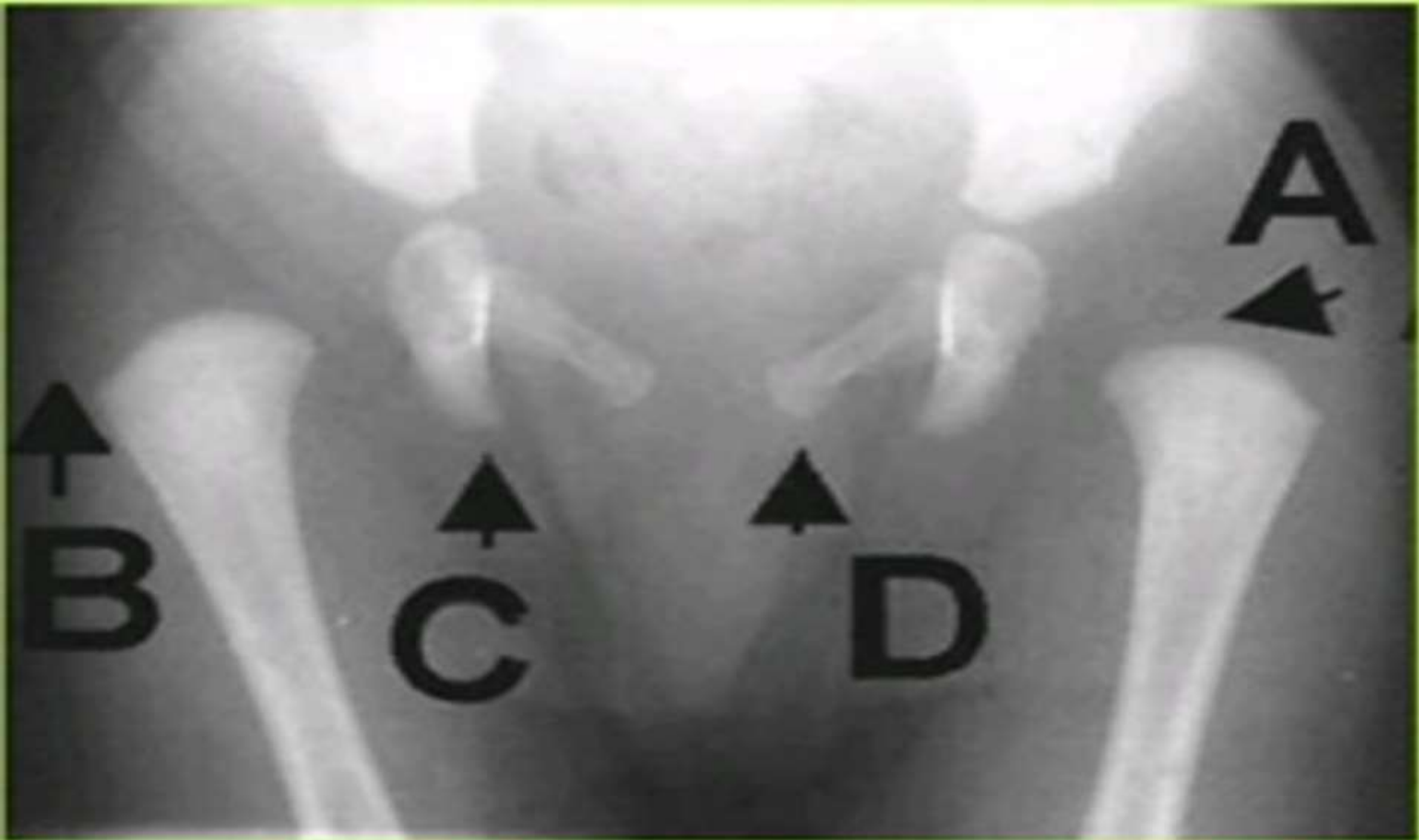
2-Adult's Wrist and Hand, showing the white lines at the end (epiphysis) of the long bones. These areas, called the epiphyseal lines, form when the growth plates turn to bone.

1



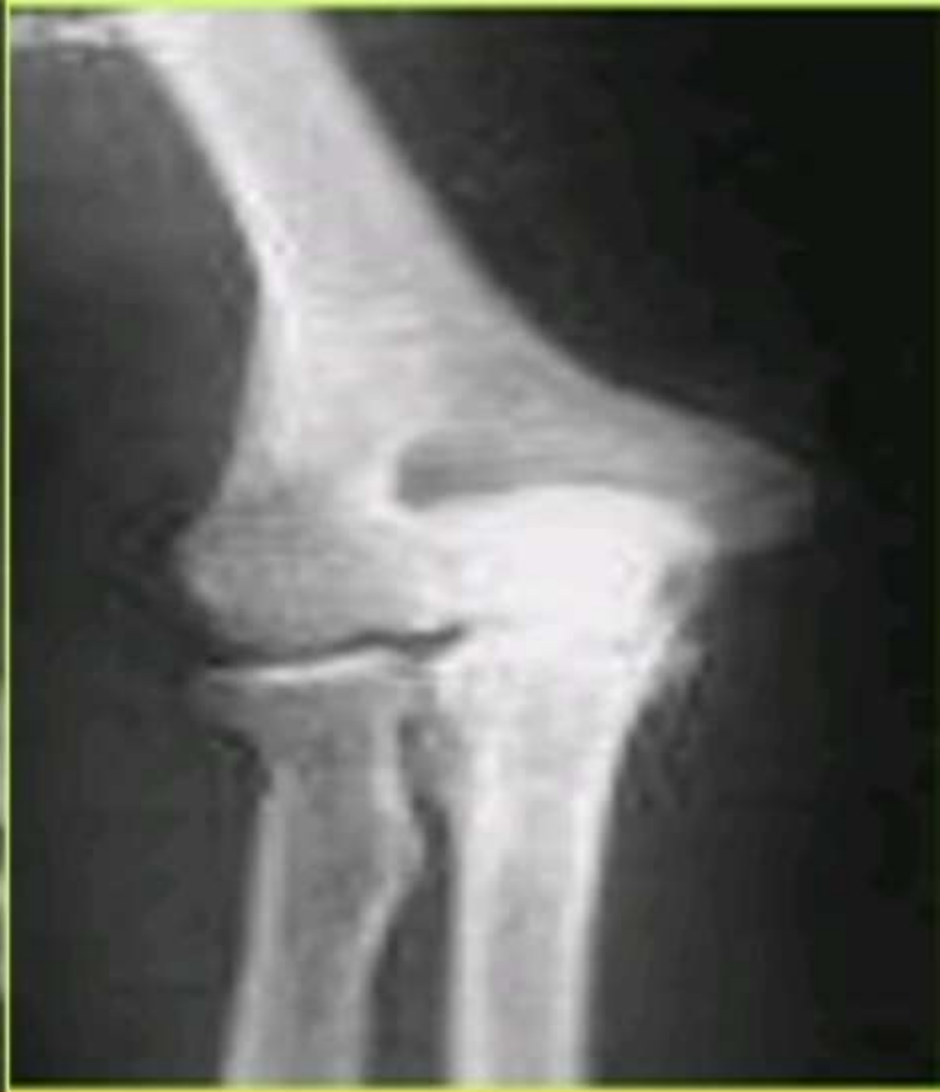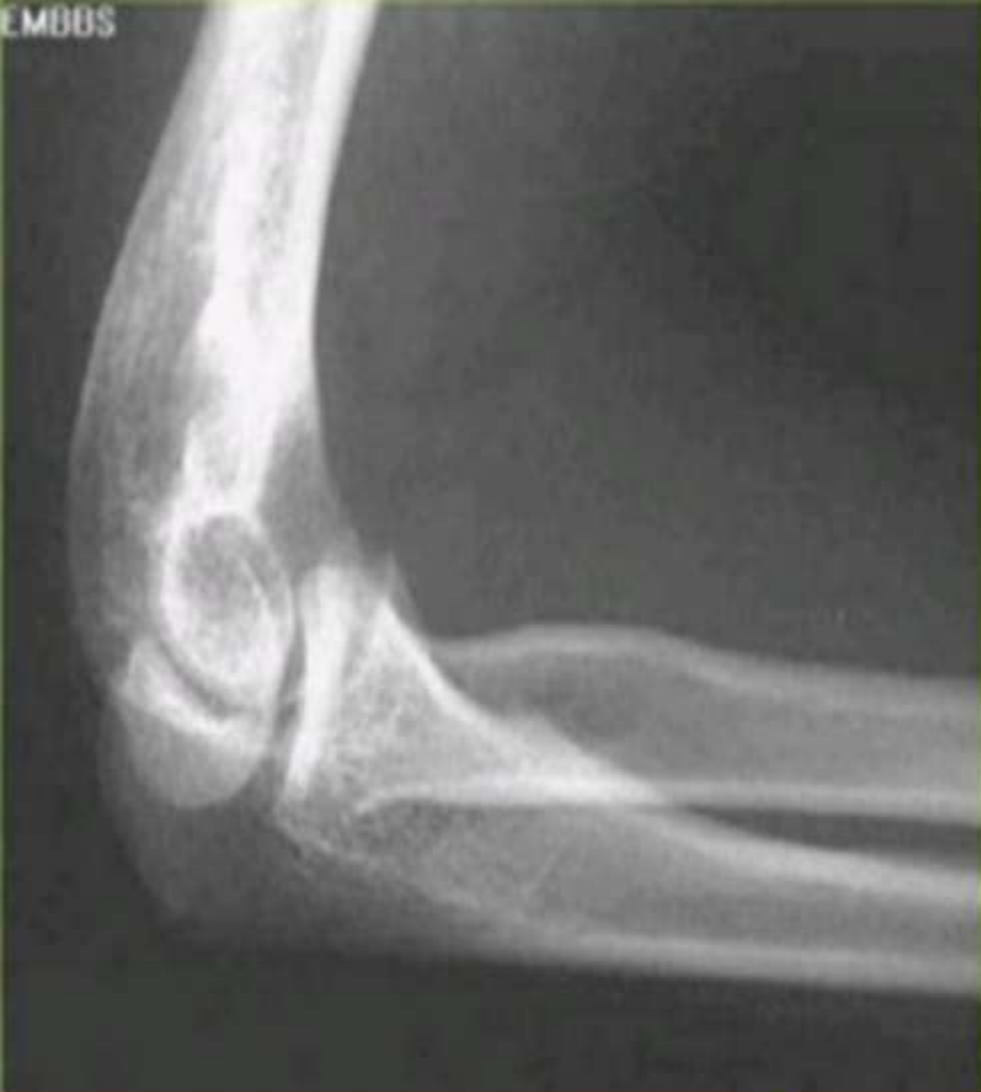2



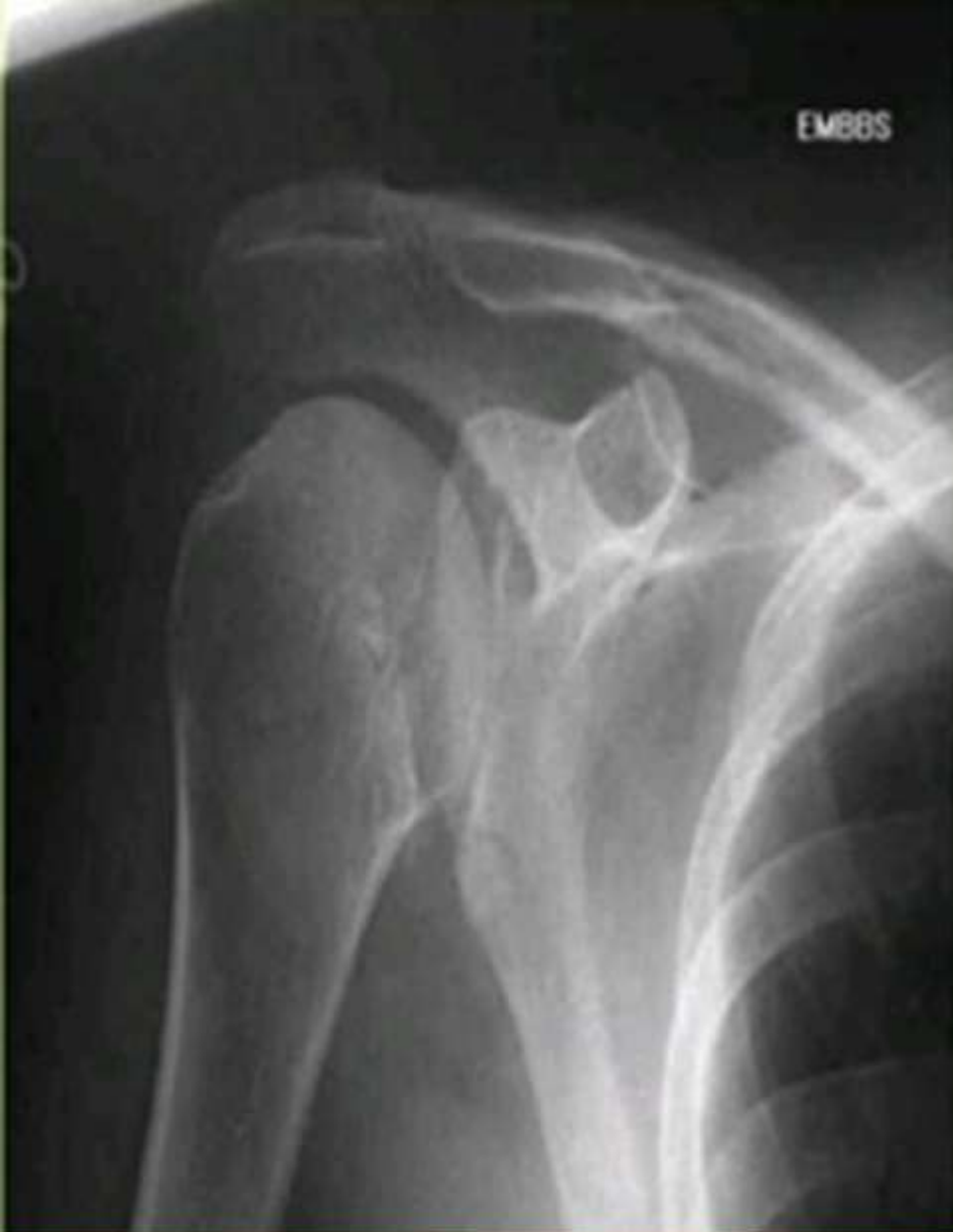

Below one year

Ossific center of the head of the femur is not appeared

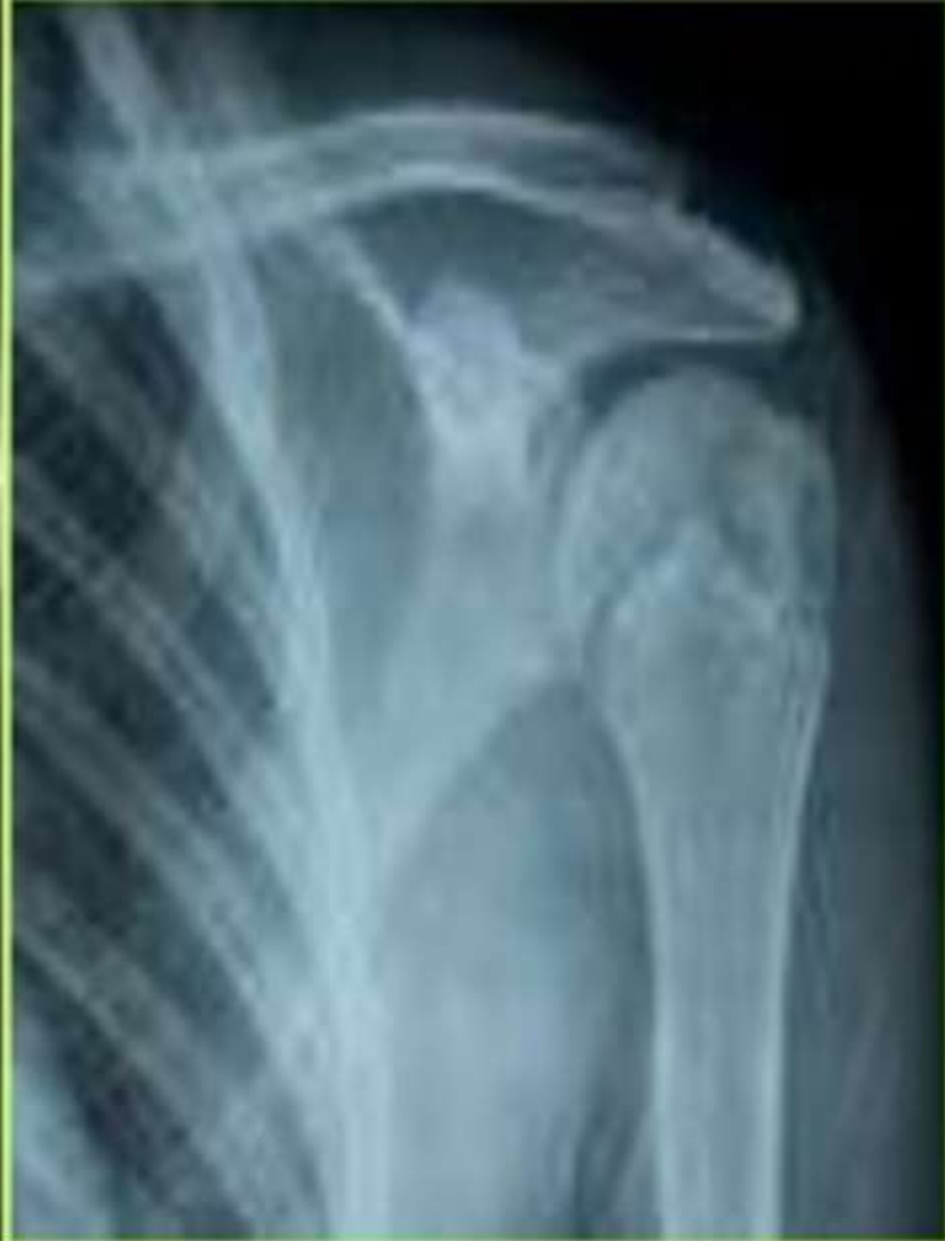

Above 17 years
Elbow joint
Complete development



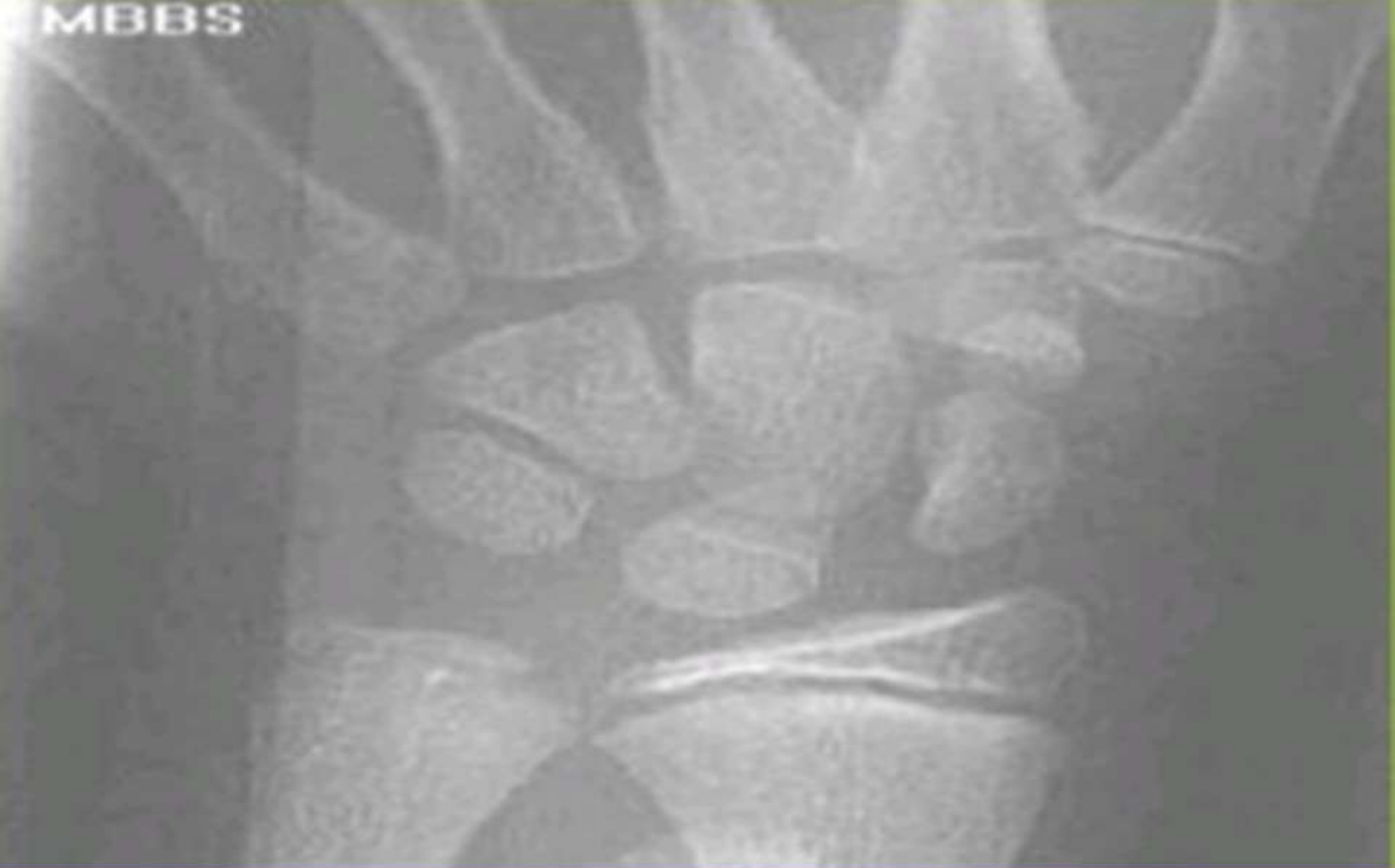Above 19 years

Union of the head of humerus



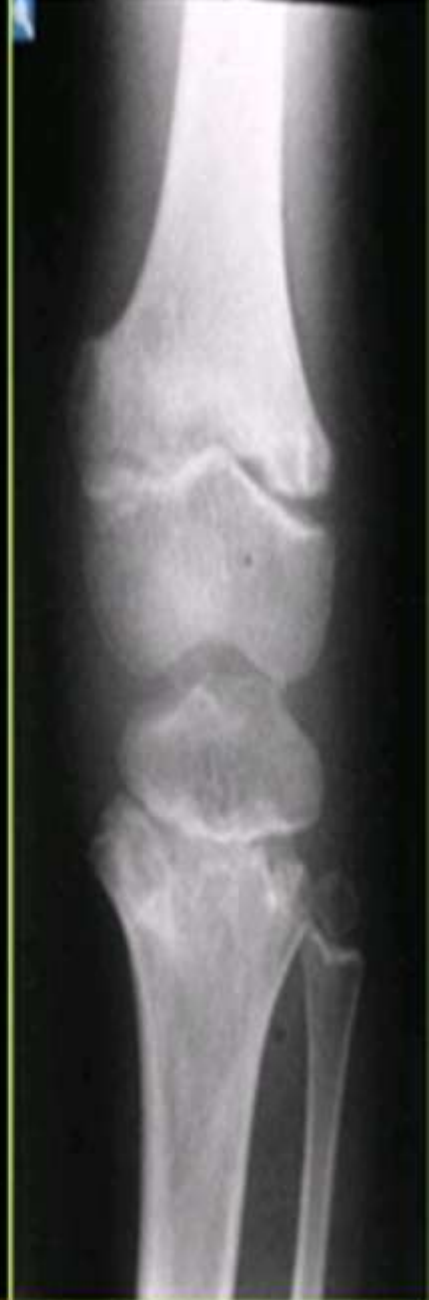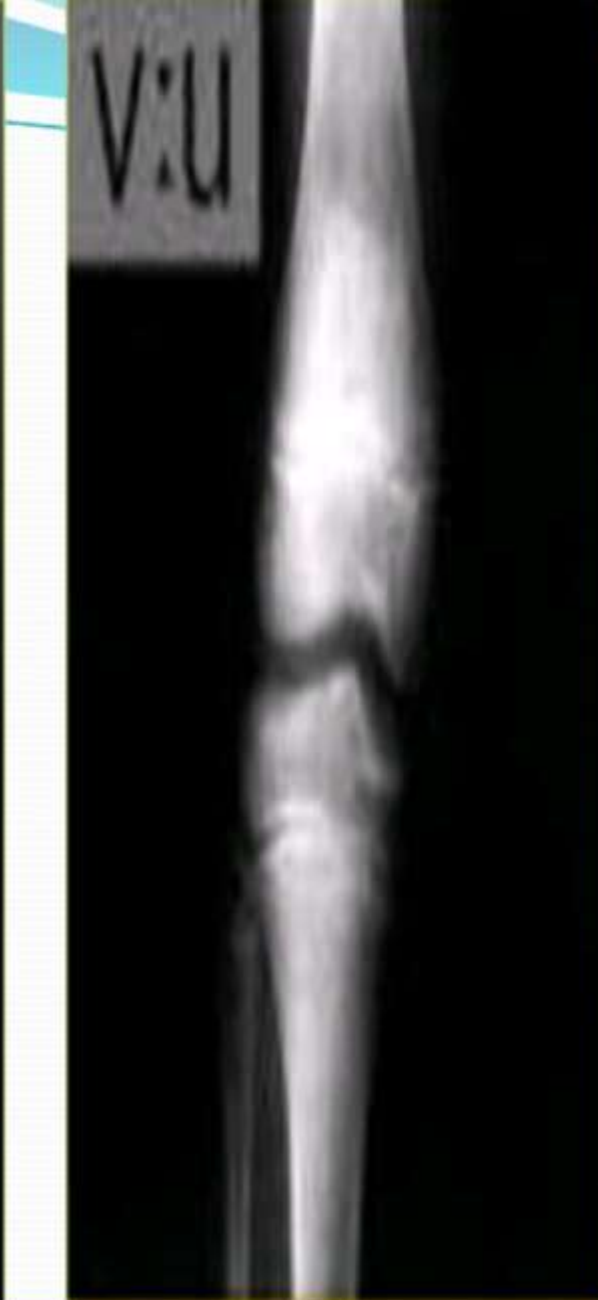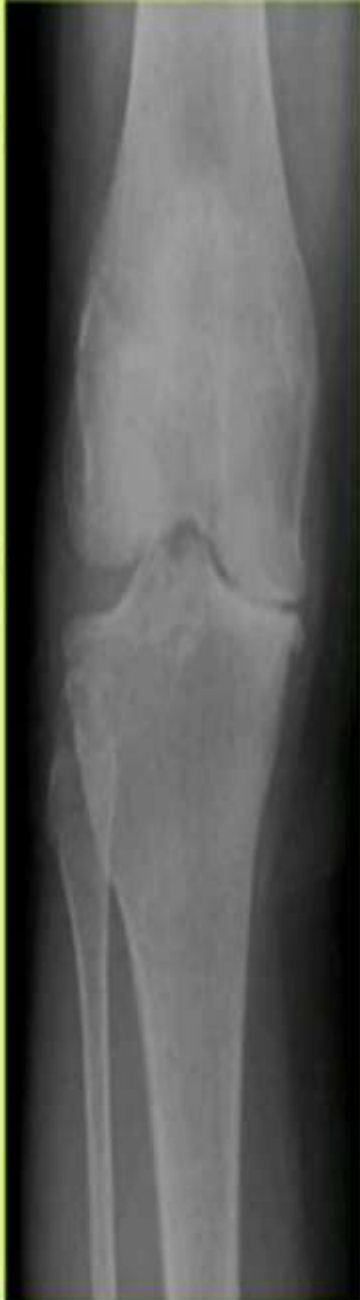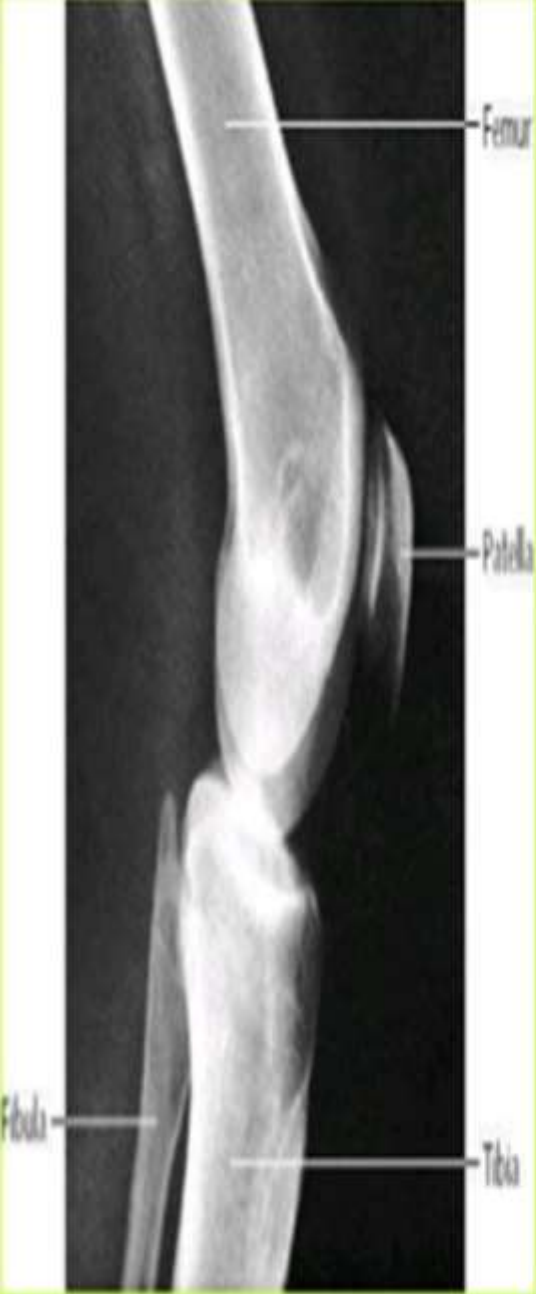below 19 years

Non -union of the head of humerus



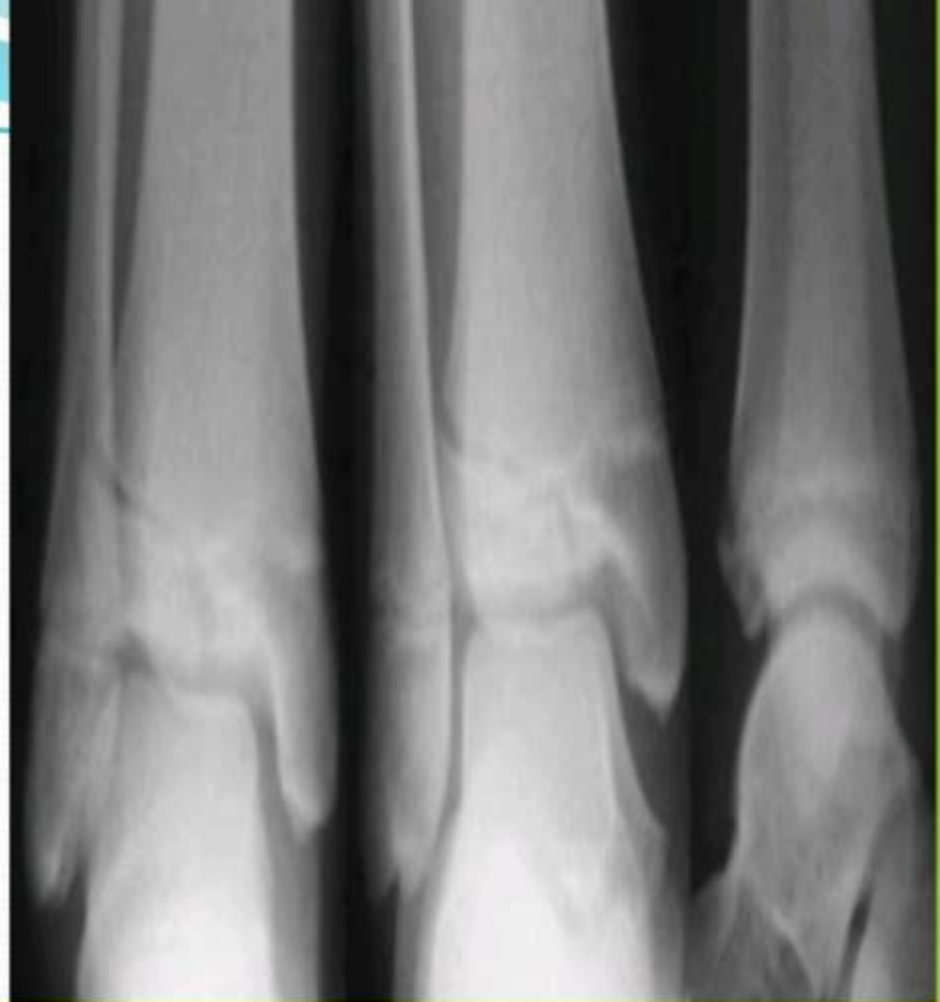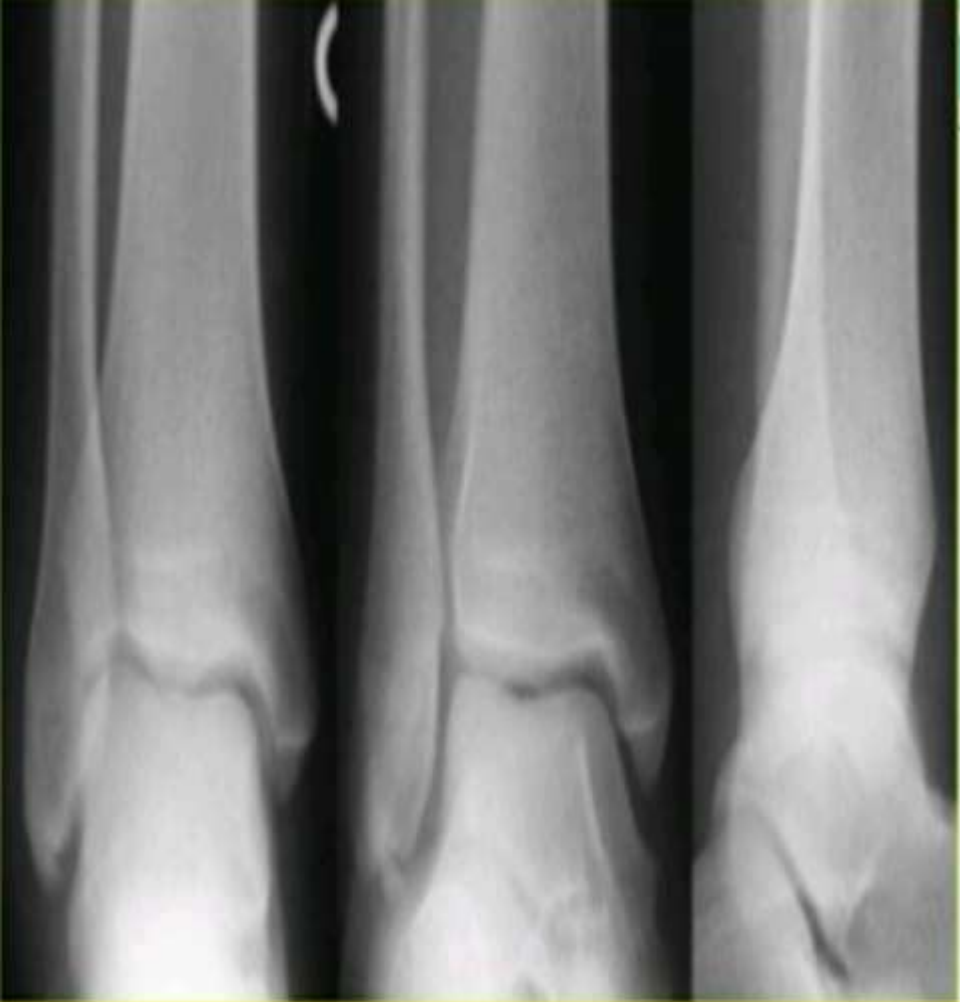Below 20 years

Non union of lower end of the radius and ulna



Above 21 years

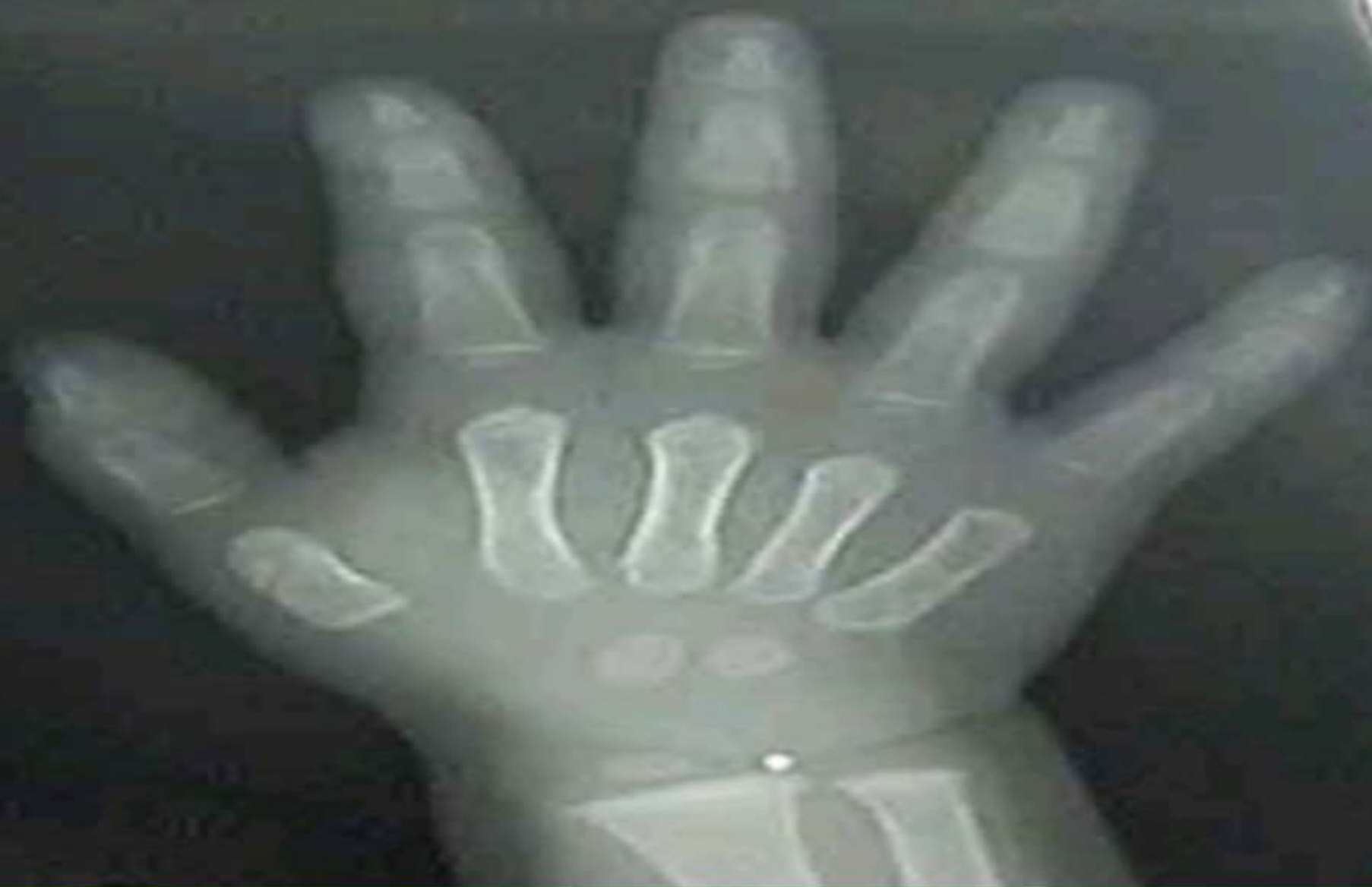Below 21 years



Above 18 years

Below 18 years

Ankle joint



Above 2 years

Appearance of ossific center of the lower radius

Thank you