

Medico-Legal Aspect of Wounds

By

Dr/Said Said Elshama

Professor of Forensic Medicine and Clinical Toxicology

Medical Education (DHPE)

College of Medicine - Taif & Suez Canal University

● Definition :-

**Application of violence on tissue of the body →
interference of continuity of tissue →wound**

●Types and shape of wounds depends on :-

1- Nature of the force

Blunt

Sharp

2- Amount of the force

Mild

Moderate

Heavy

Classification of Wounds :-

A – Legal Classification

B – Medico legal Classification

A – Legal →

1-Slight

2- Dangerous

3- Mortal

B – Medico legal Classification :-

1-Abrasion

2- Contusion (bruises)

3- Cut (incised)

4- Contused (lacerated)

5- Stab

6- Firearm

7- Fabricated

Abrasion :-

1-Defintion

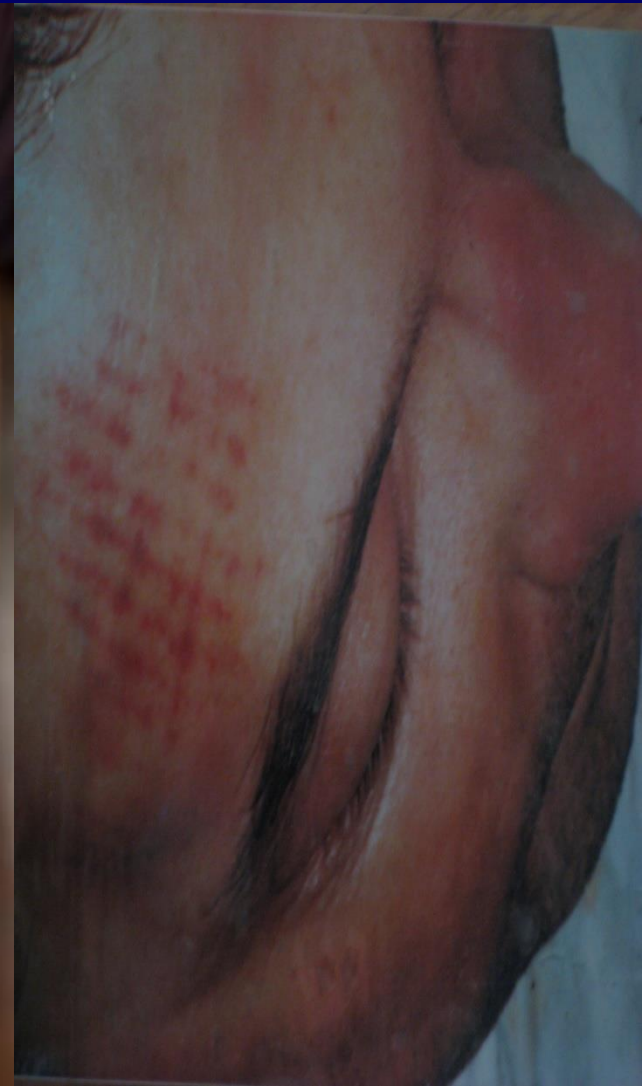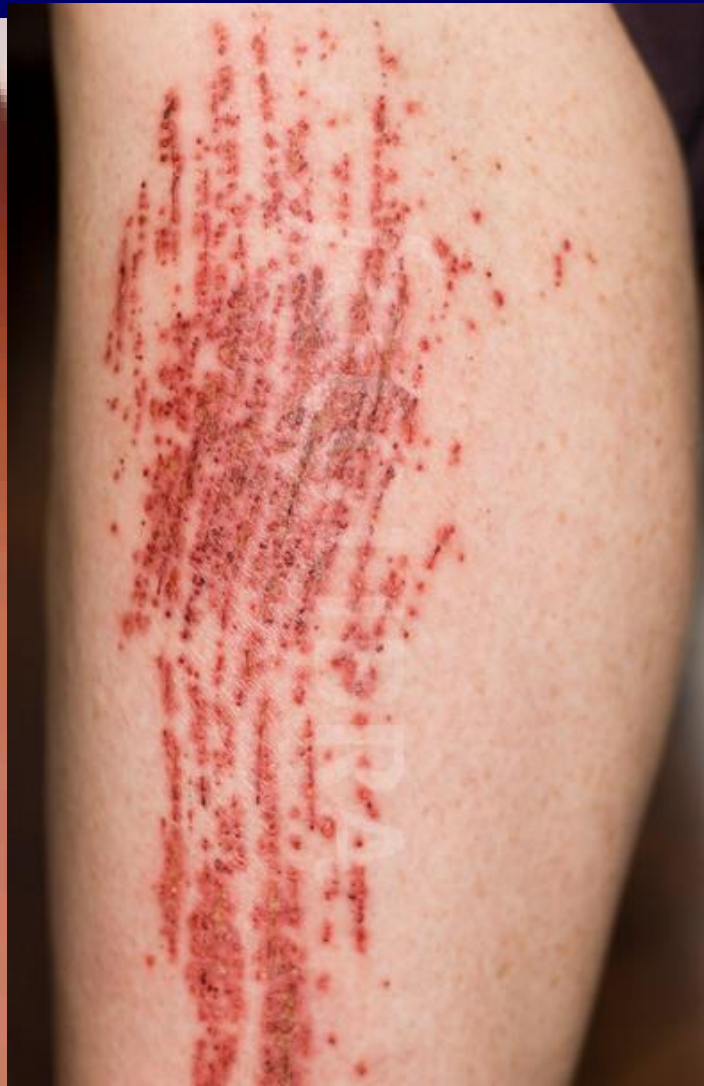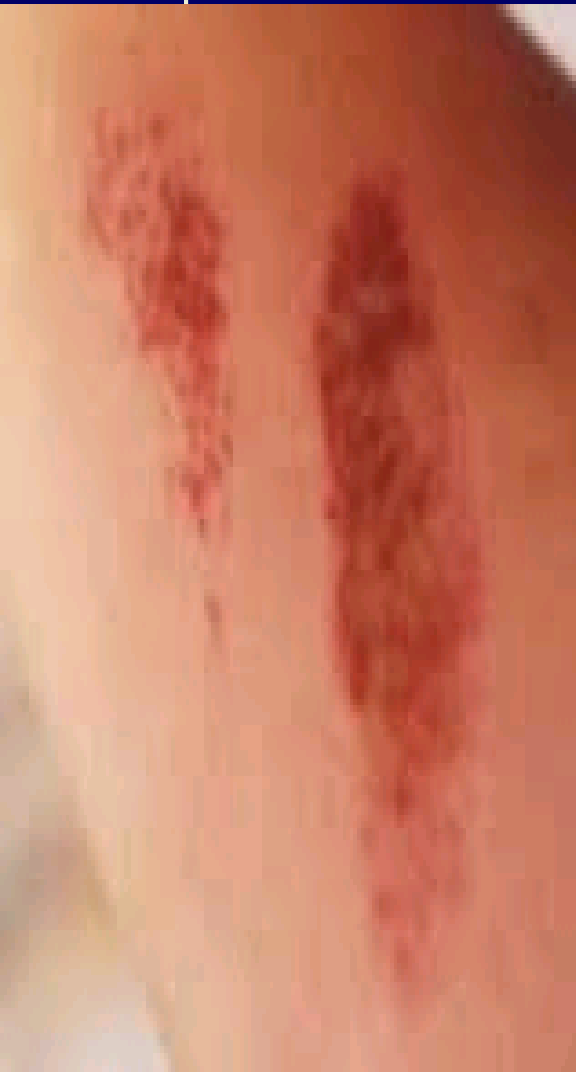2-Types

3-Age

4-Ante - Mortem

5-Post - Mortem

Abrasions



Contusions (Bruises):-

1-Defintion

2-Factors Affecting

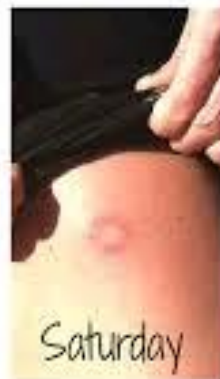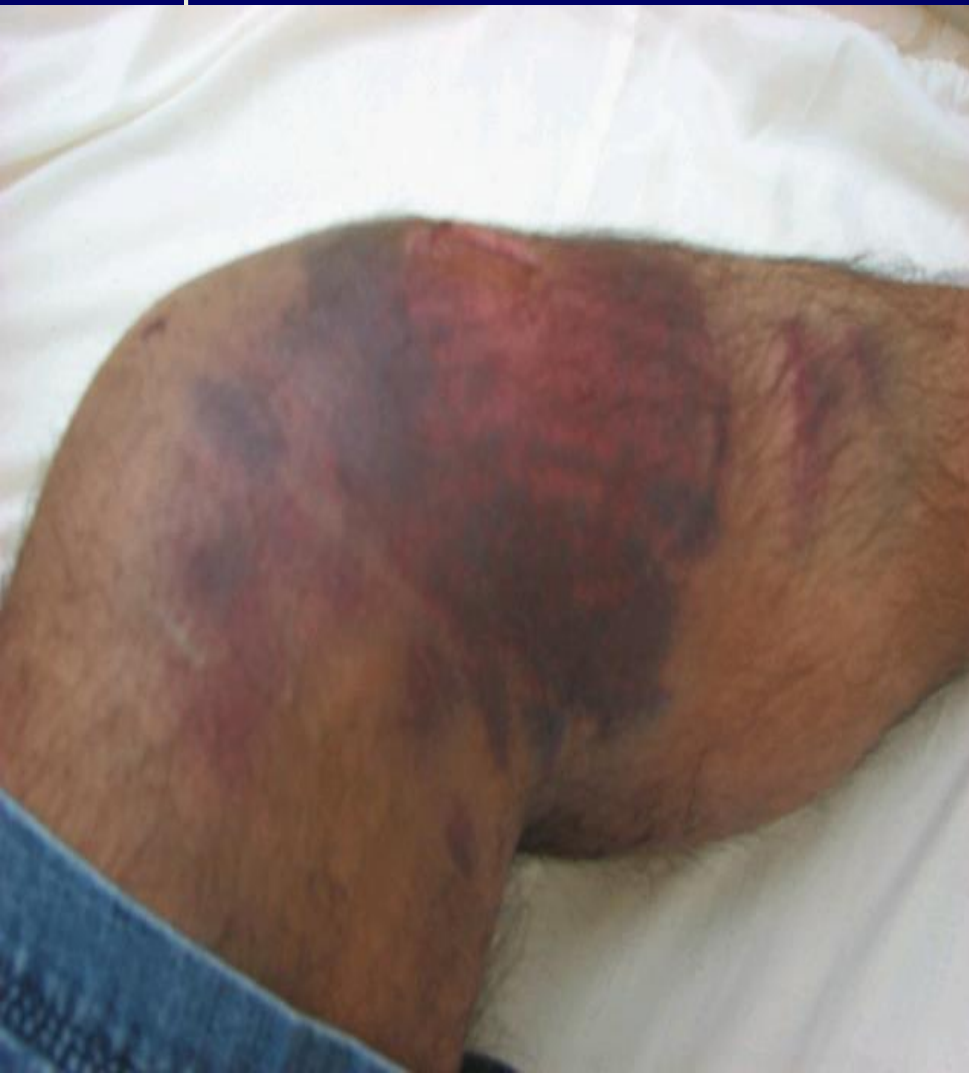(size , site , shape)

3-Age

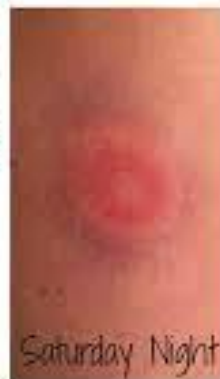4-Ante - Mortem

5-Post - Mortem

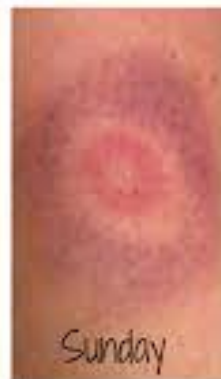Bruises



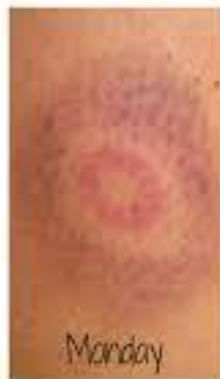Saturday



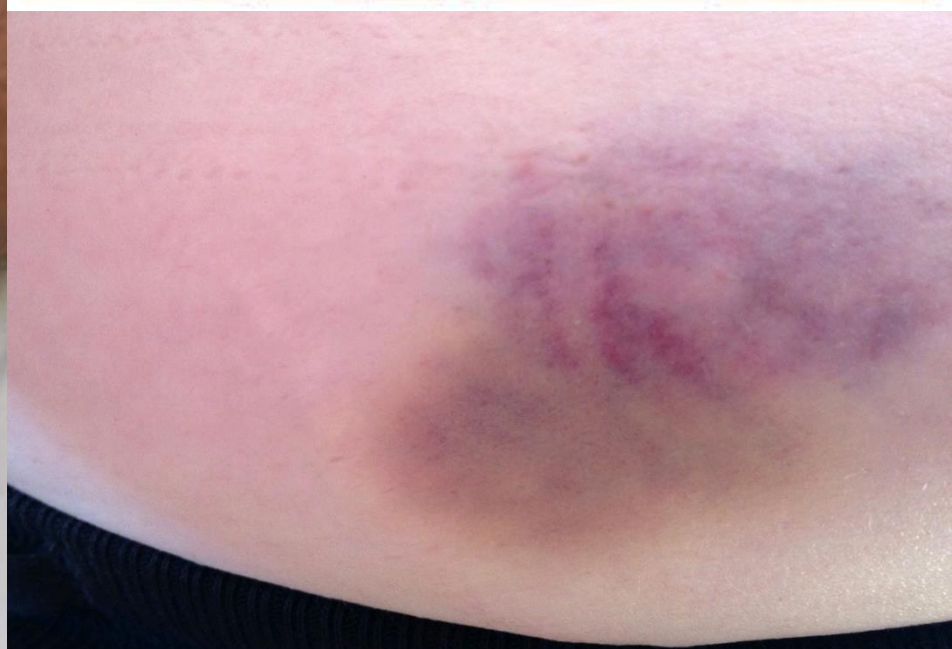Saturday Night



Sunday



Monday

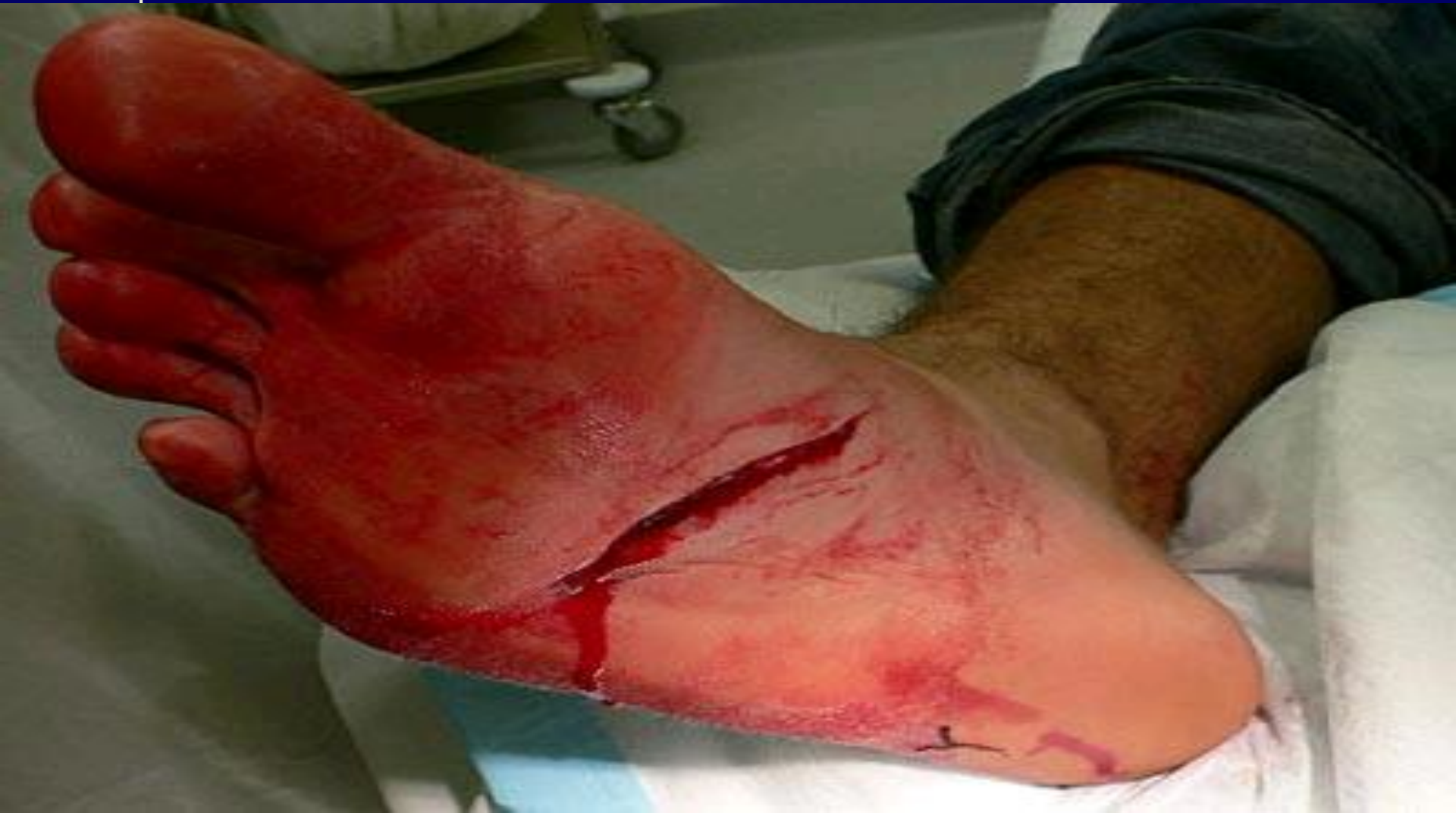

Cut (Incised) Wounds :-

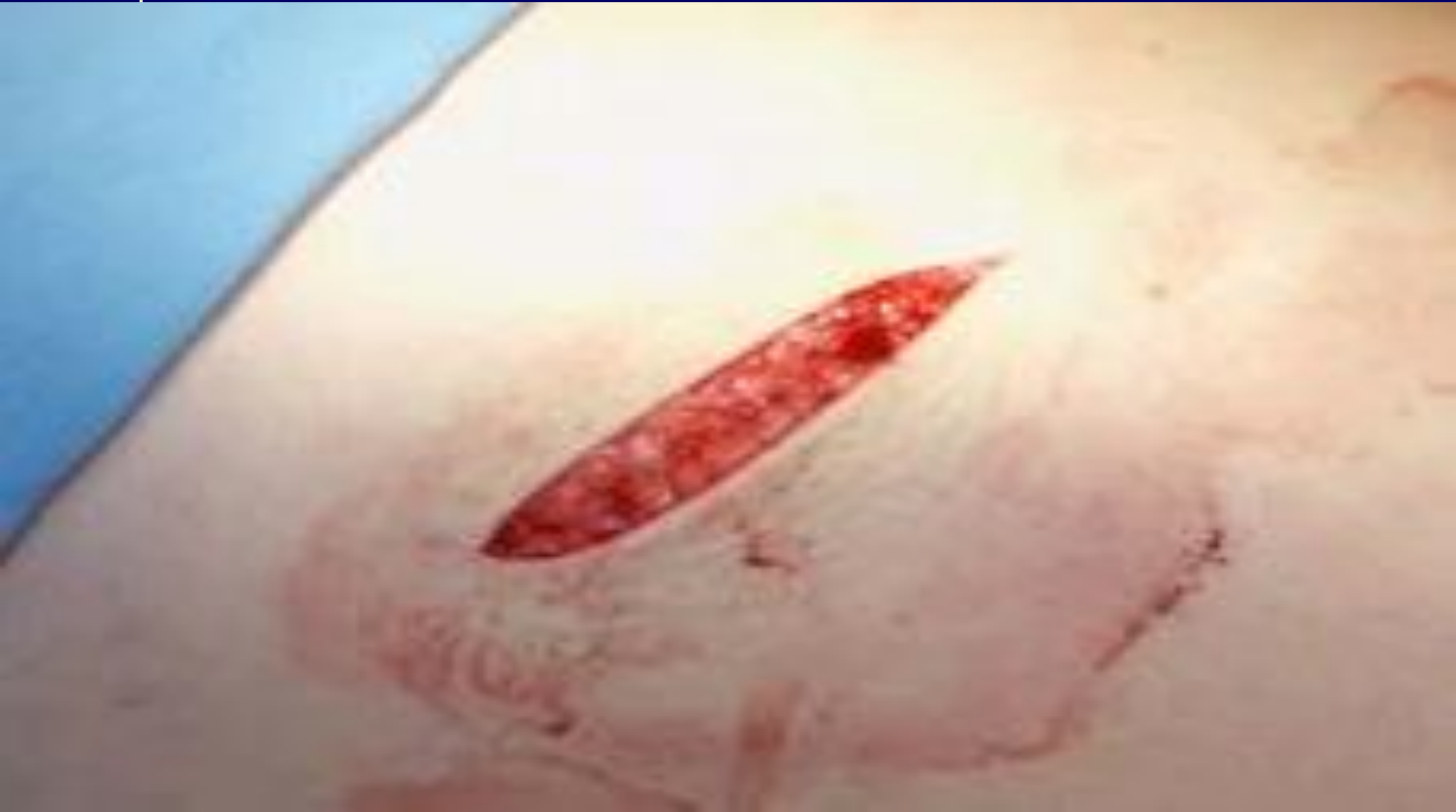Characters :-

- 1- Causative instrument
- 2- Edge
- 3- Length
- 4- Bridging of tissues
- 5- Hair
- 6- Bleeding
- 7- Sepsis

Cut Wound



Cut Wound

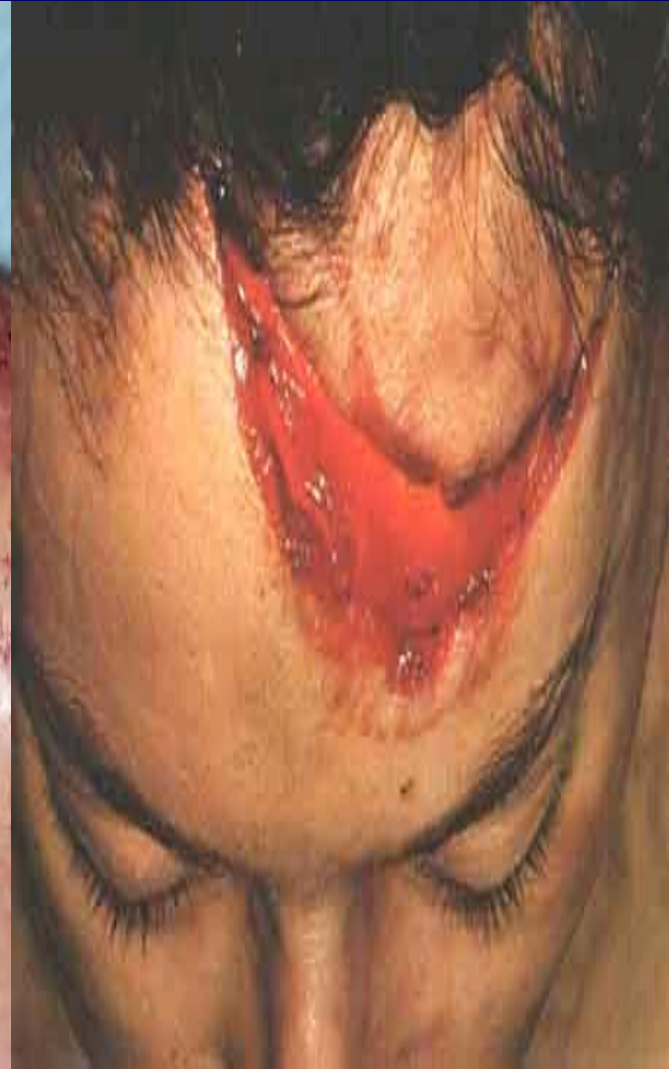
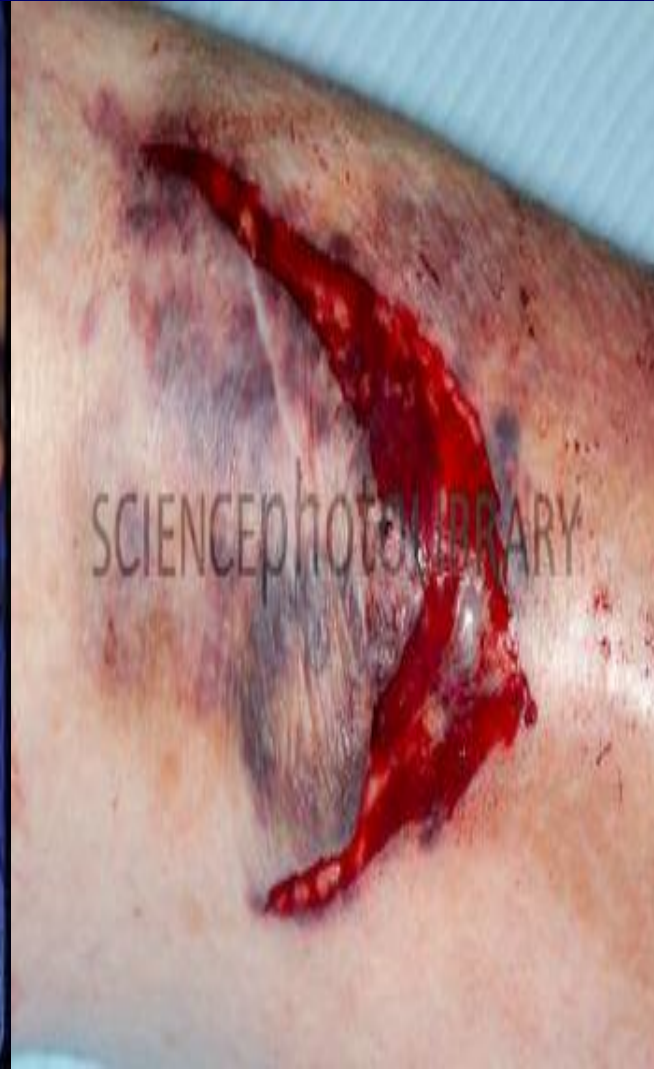
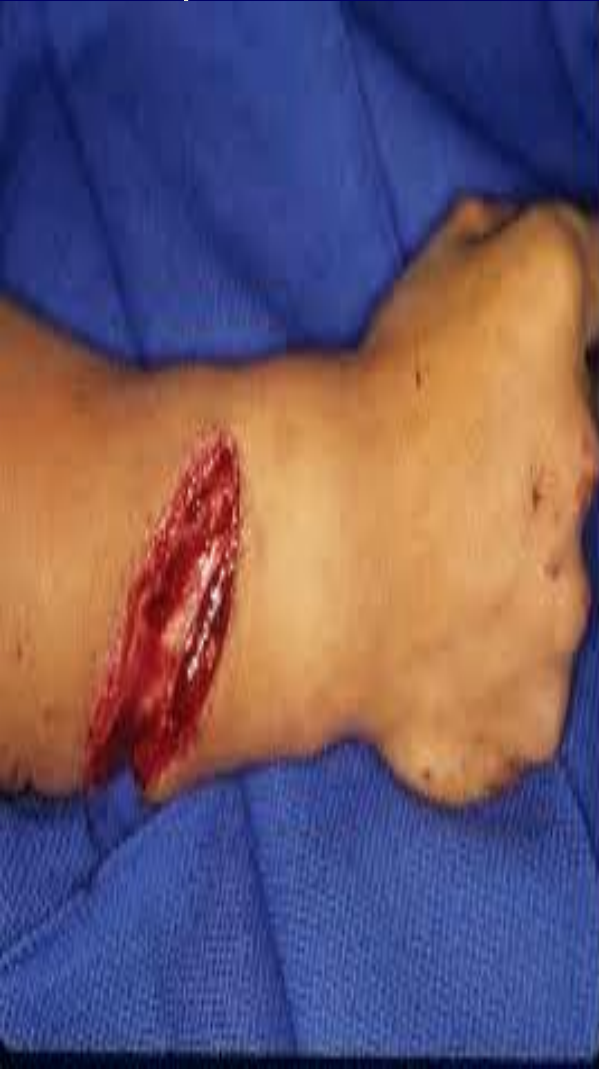Contused(Lacerated) Wounds :-

Characters :-

- 1- Causative instrument
- 2- Edge
- 3- Bridging of tissues
- 4- Hair
- 5- Bleeding
- 6- Sepsis

Lacerated wound (Contused)



Stab Wounds :-

Characters :-

1- Causative instrument

2- Edge

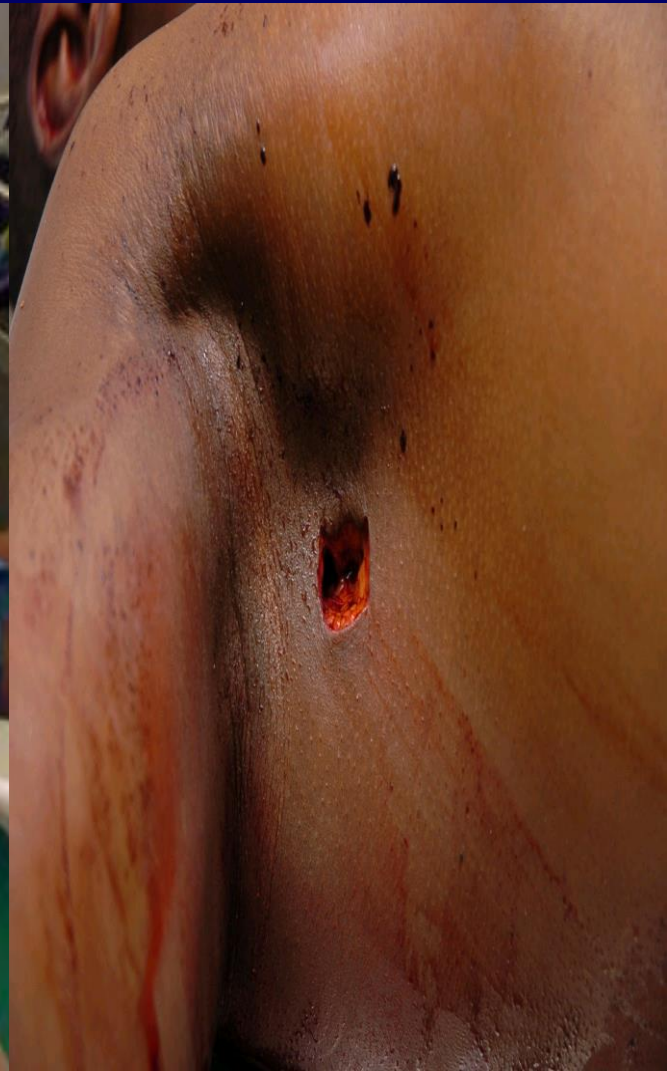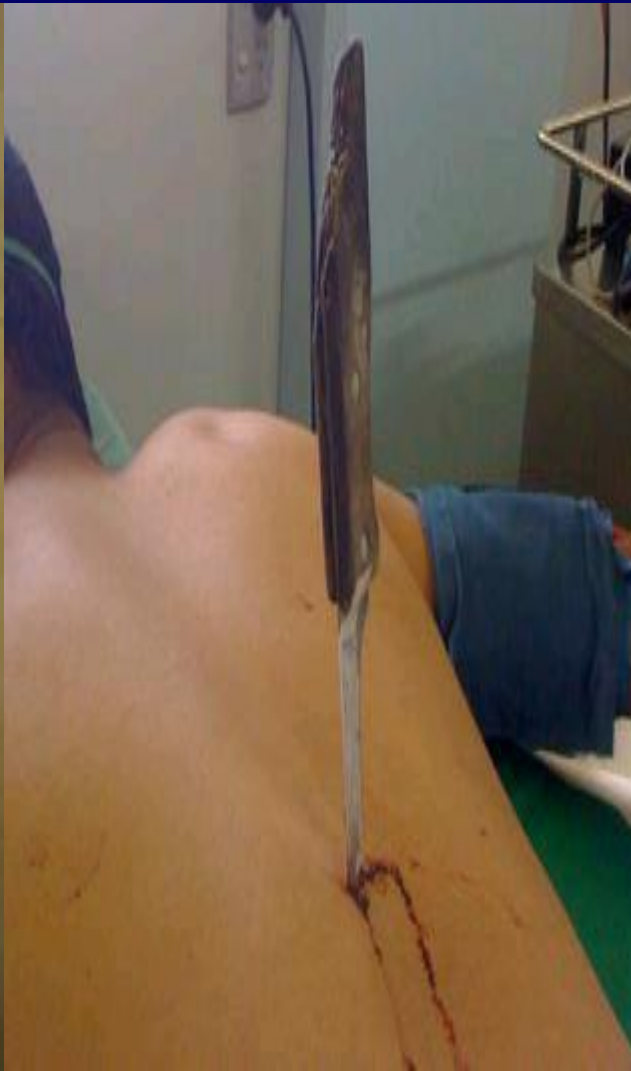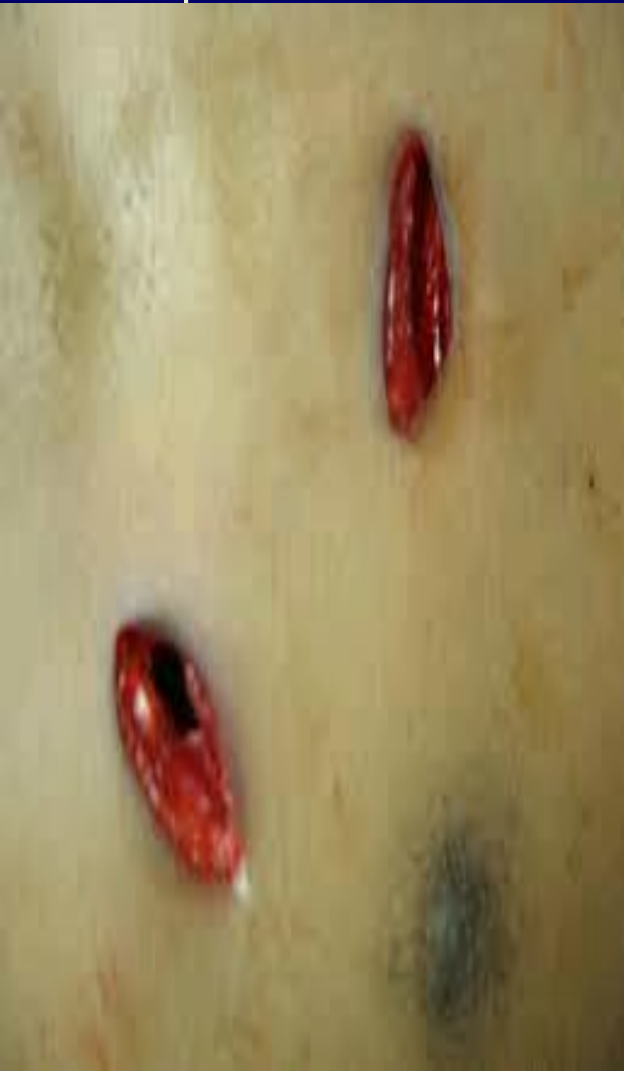3- Depth

4- Angle

5- Types → 1- Penetrated

2- Non Penetrated

Stab Wound

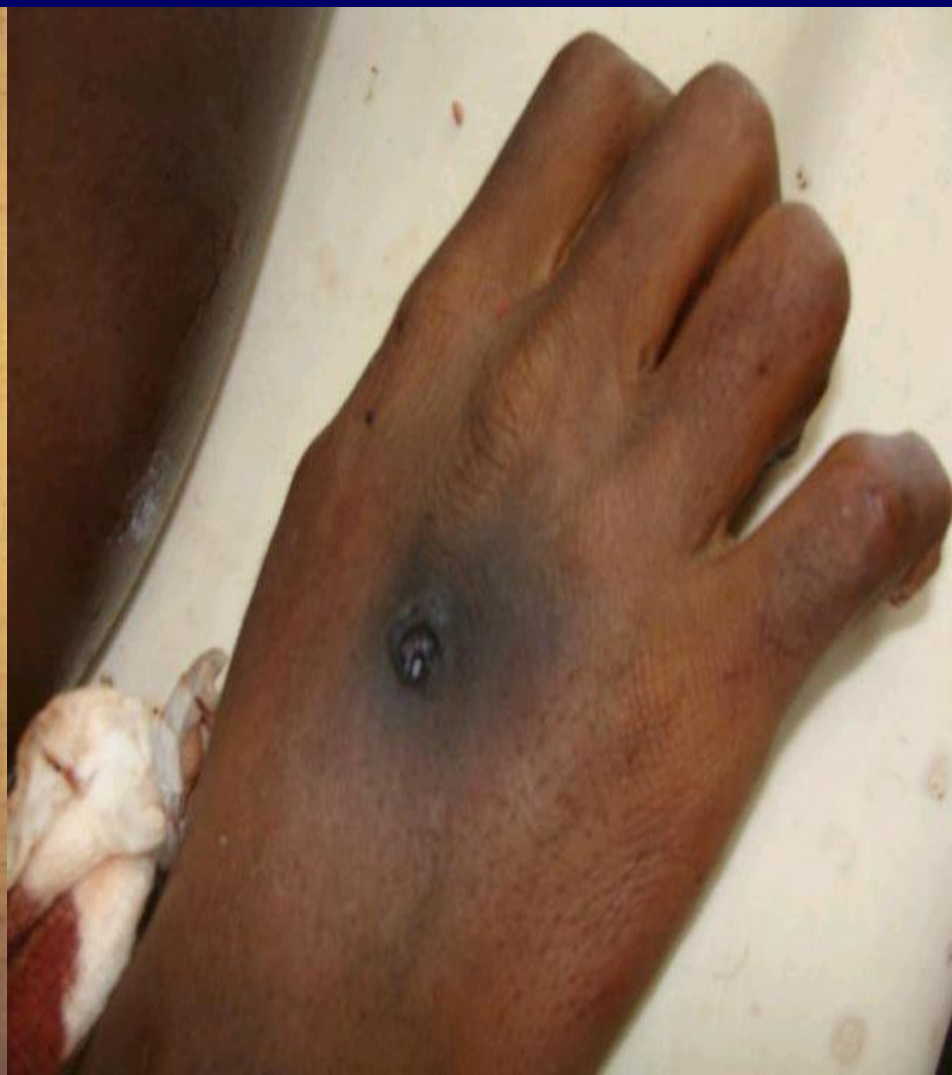
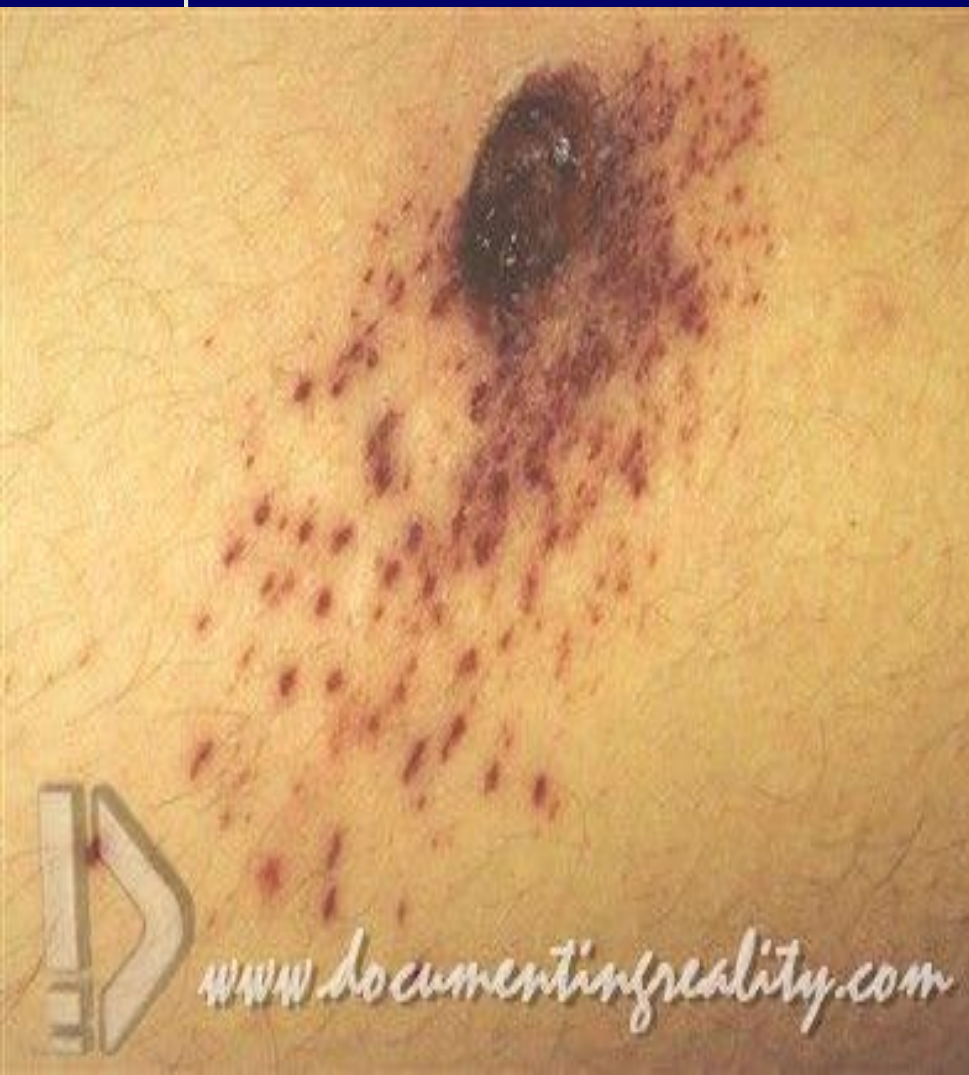
Firearm Wounds :-

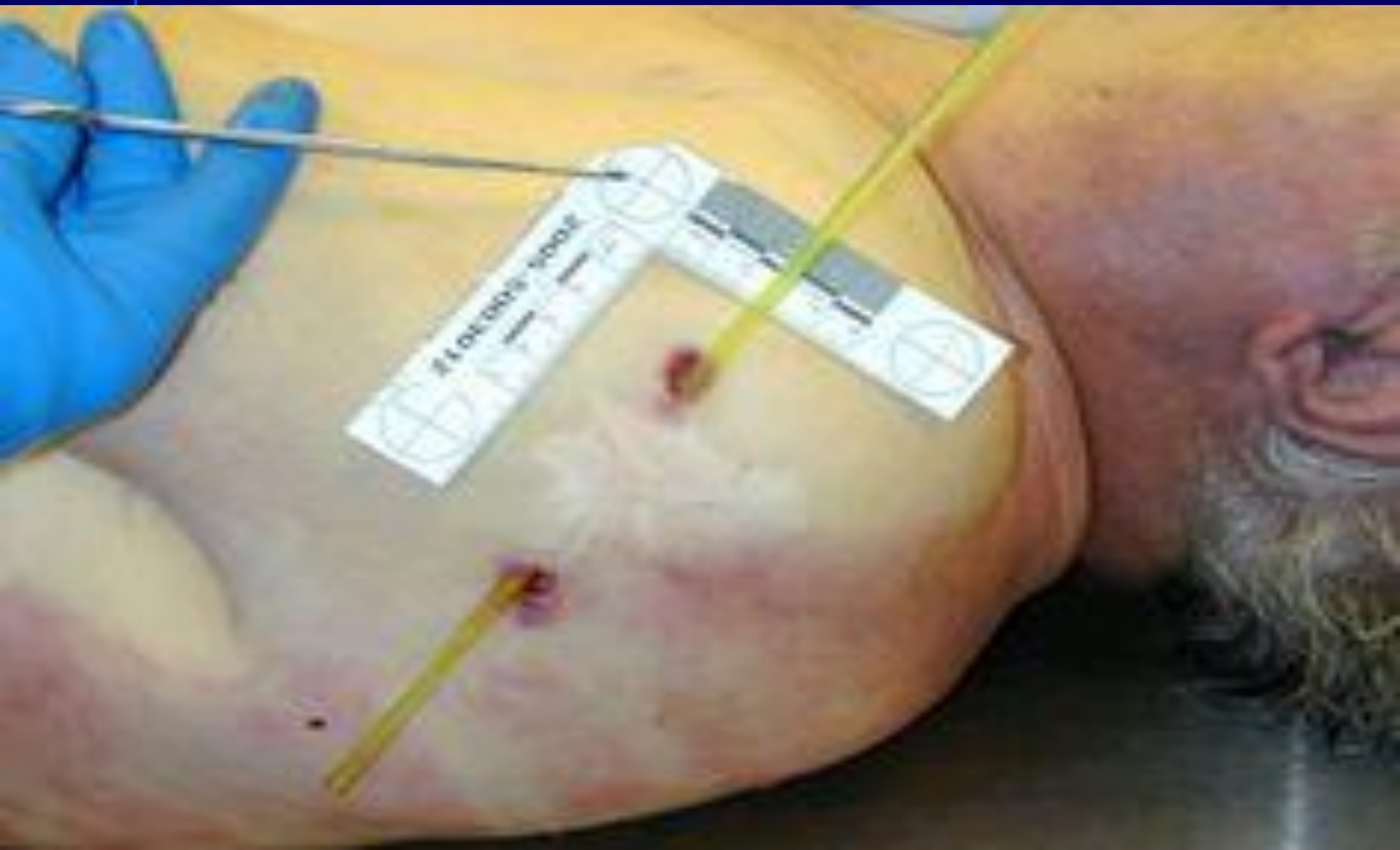
Characters:-

- 1- Loss of substance
- 2- Presence of two wounds
(Inlet and Exit)
- 3- Powder marks
- 4- Beveling

Firearm Wound



Entry and Exit points of Firearm Wound

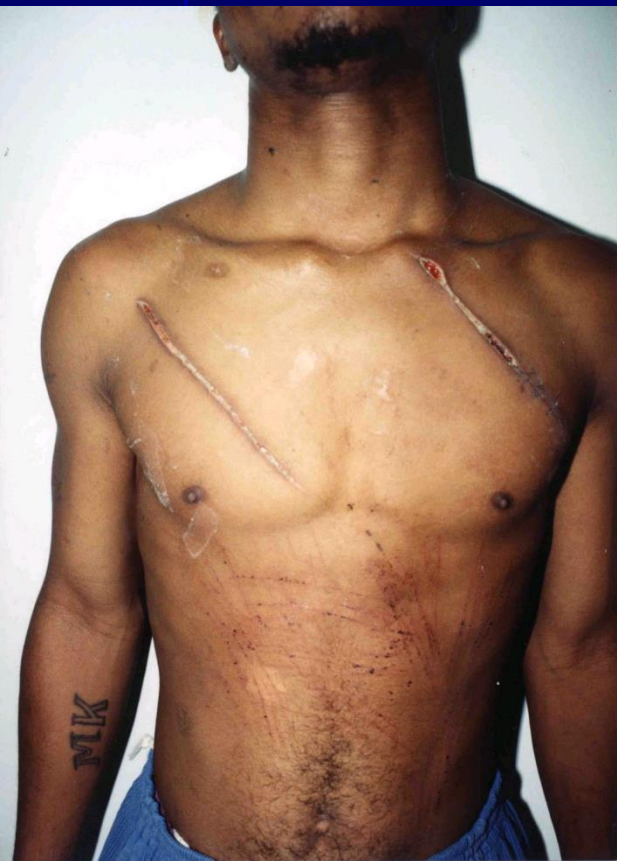

Self Inflicted Wounds :-

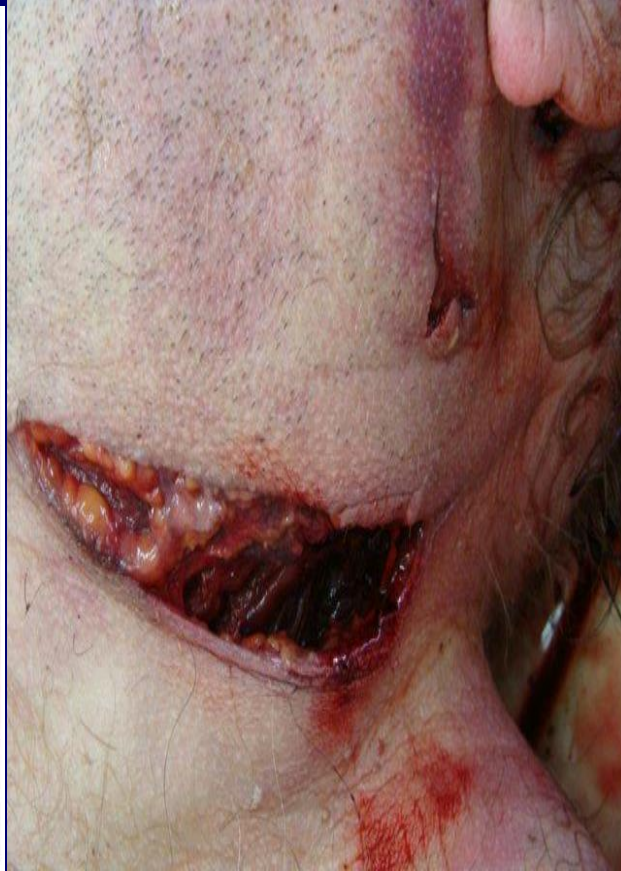- 1- Cut wrist**
- 2- Cut throat**
- 3- Firearm**
- 3- Fabricated**

Self Inflicted Wounds

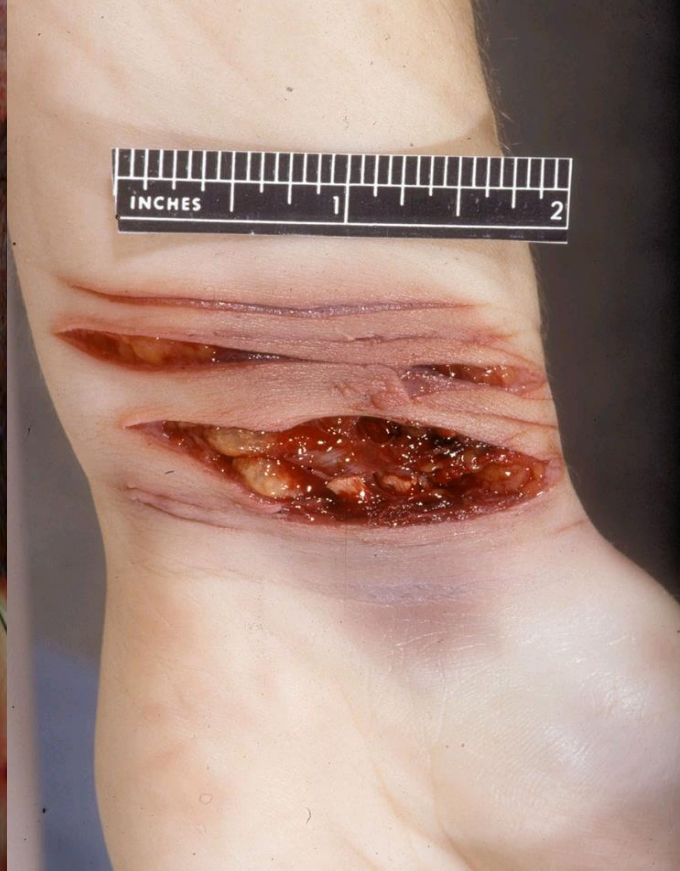Fabricated



Cut Throat



Cut Wrist



Age of Wounds:-

After 24 hr → red and swollen

After 48 hr → new vessels grow

After 5 days → obliterated vessels

After 10 days → healing by primary intention

After 3 weeks → red scar

After 3 months → coppery scar

After 6 months → pale scar is undetectable

Examination of Wound

- **Nature of wound**

(suicidal, homicidal, accidental)

- **Site of wound**

(neck, wrist, heart, temple, back)

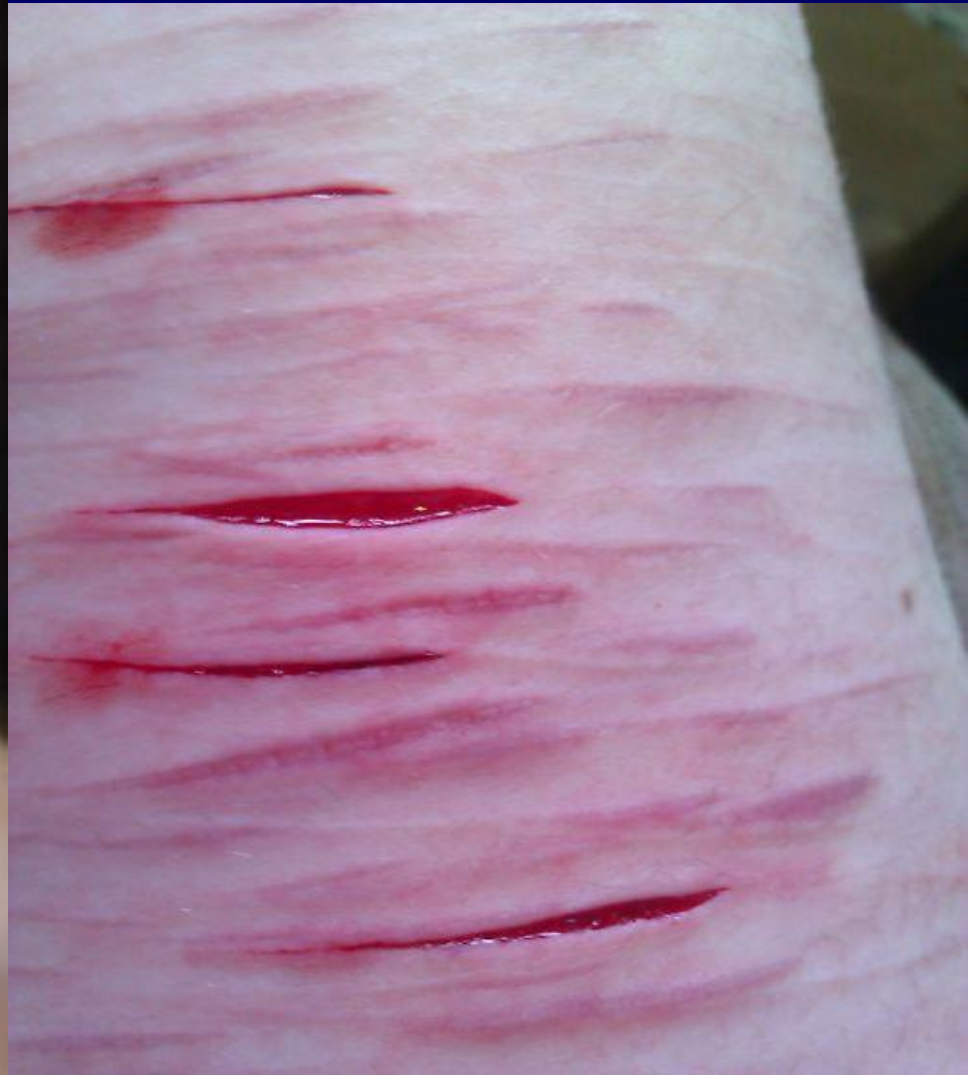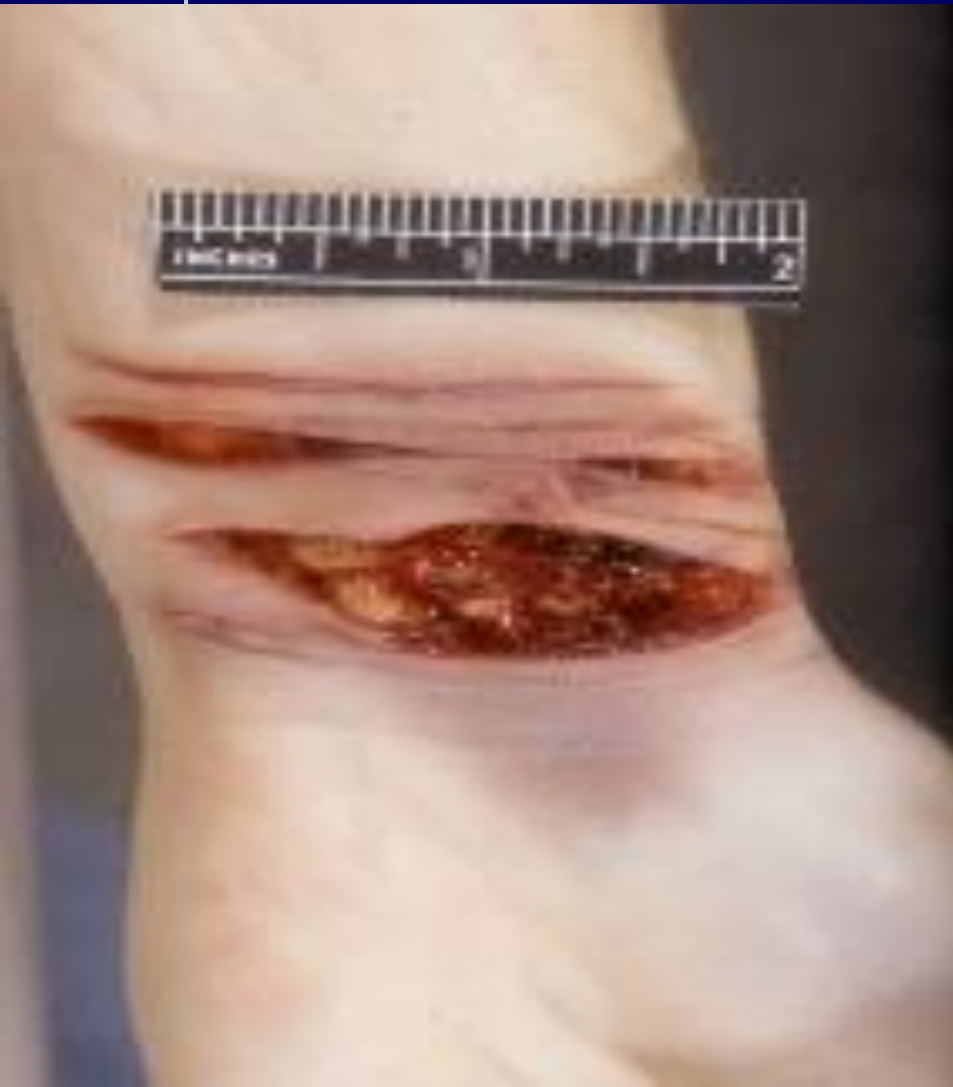- **Direction of wound**

(oblique, transverse, downwards, backwards, inwards)

- **Number of wounds** (multiple or single)

- **Hesitation mark** (suicide)

Hesitation Marks



Complications of Wounds :-

1- Traumatic shock :-

A- Primary

B- Secondary

2- Hemorrhage

3- Embolism:- (Venous , Arterial)

A - Air

B - Fat

4- Infection

5- Surgical interference

Thank you