

Medico-legal aspect of Road Traffic accidents

By

Dr. Said Said Elshama

Professor of Forensic Medicine and Clinical Toxicology

Medical Education (DHPE)

College of Medicine - Taif & Suez Canal University

Objectives

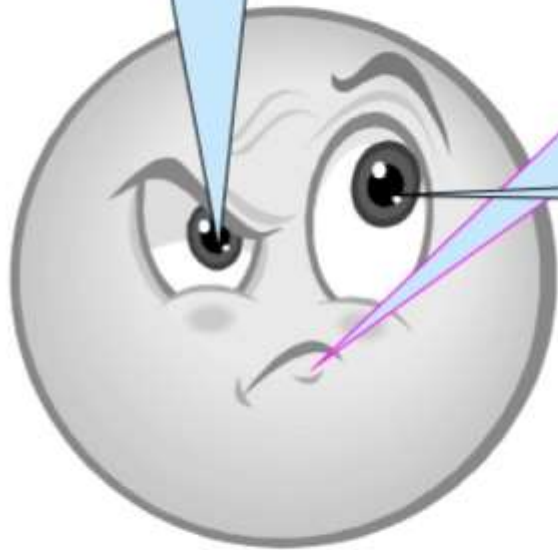
- 1- What are the road traffic accidents ?
- 2- Pattern injuries to Pedestrians
- 3- Factors affecting pedestrian injuries
- 4- Vehicle occupants injuries
- 5- How to investigate the road traffic accident by forensic expert ?
- 6- Motorcycle & Cycle Injuries



Pedestrian

**Occupants of vehicle
(driver and passenger)**

Cyclist / motorcyclist



The road traffic accidents

Pattern injuries to Pedestrians

1- Primary impact Injuries

First impact of the victim by the vehicle

2- Secondary impact Injuries

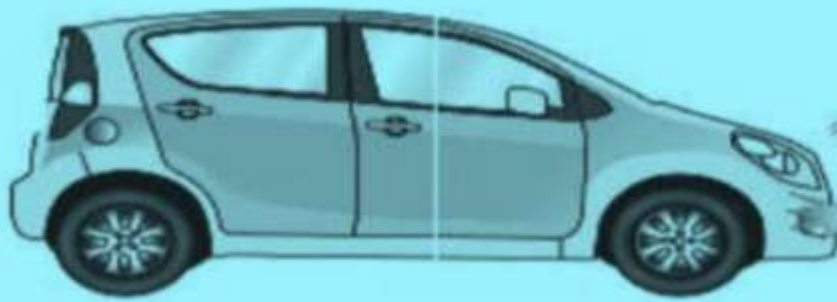Subsequent impact of victim by the same vehicle.

3- Secondary or Tertiary Injuries

The victim was struck by another vehicle or other objects such as electric pole, tree or the ground

4- Run-over Injuries

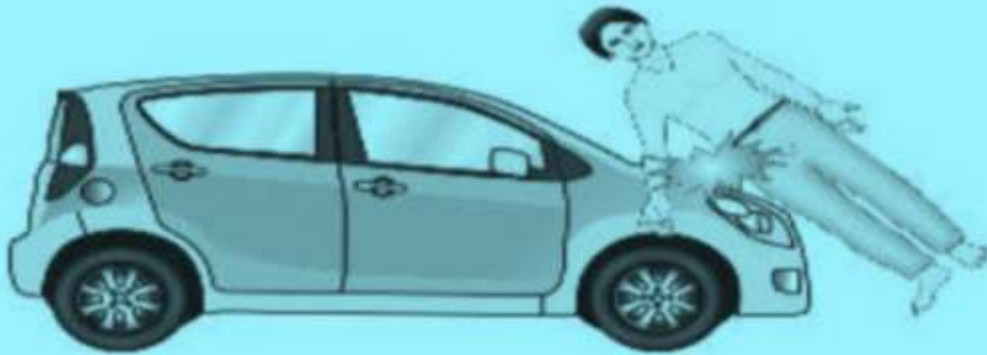vehicle runs over some part of victim



Bumper
impact



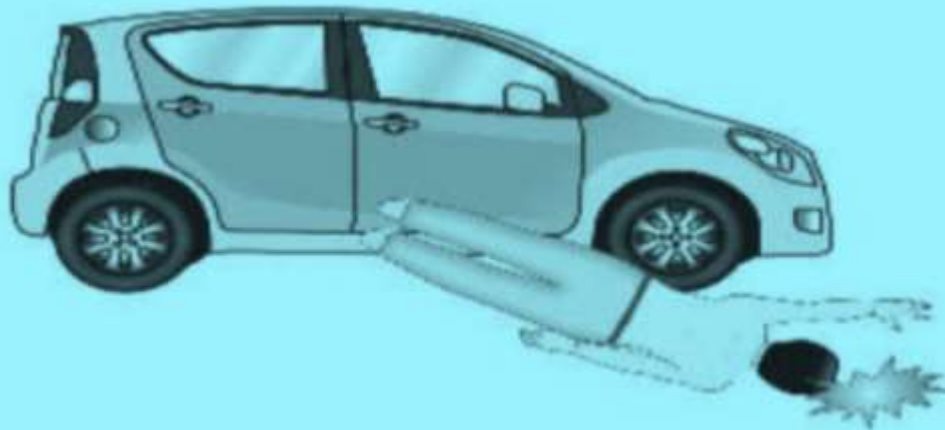
Primary
impact
injury



Hood and
Windscreen
impact



Secondary
impact
injuries



Ground
impact



Secondary
injuries

Factors affecting pedestrian injuries

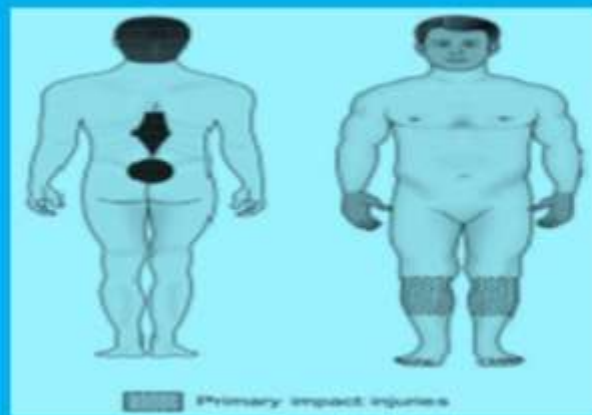The body part that suffers from the injury depends on the position of pedestrian and Vehicle:-

- 1. Pedestrian is standing, walking or lying on the road.**
- 2. Pedestrian is struck by the front or side of the vehicle.**
- 3. Vehicle is braking violently at the movement of impact or not.**

because the front end of the vehicle dips down and the legs will be injured at a lower level.

Primary Impact injury

- Site of injury determines position and height of pedestrian and kind of vehicle involved in the Incident.
- It causes bumper fracture in tibia & fibula of one or both legs.



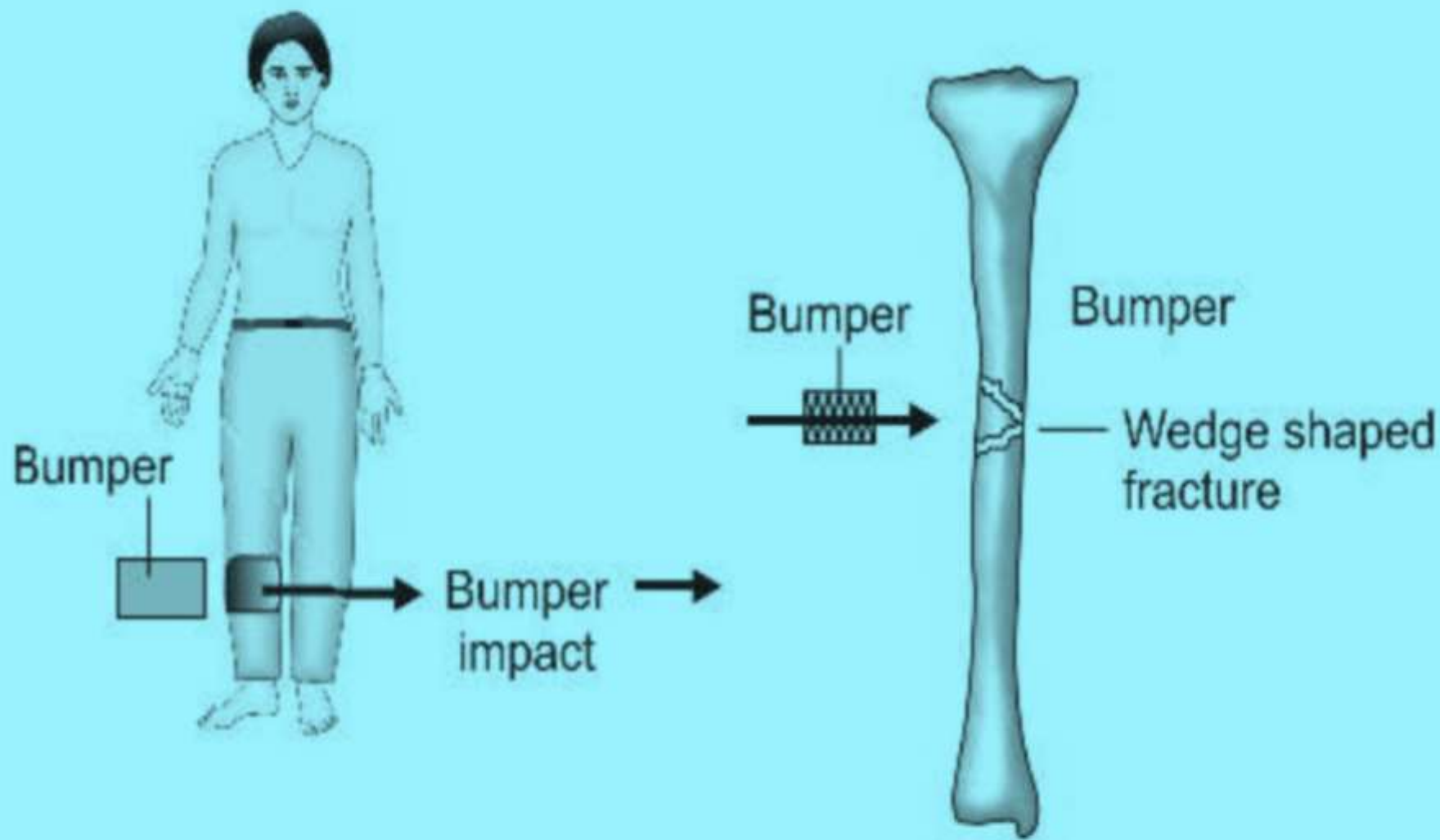
- The body of victim may bear pattern of the part of vehicle in form of imprint abrasion.
- Impact with headlamp or mudguard cause fracture of pelvis or sacroiliac joint dislocation.

Types of Primary Impact injuries

- Person was struck from behind (legs) and foot fixed → back and buttocks come in contact with vehicle → fracture- dislocation of lumbar and thoracic spine.
- If the feet side forward → the body fall backward → head impact with windshield or he is thrown into the air or to one side to strike ground.
- Facing → intra-abdominal and intra thoracic injuries or head injuries.
- Door handles → tearing wounds
- Side of vehicle → Fracture rib, rupture lung, liver and spleen.

Bumper Fracture

- Bumper fracture involves tibia and produces femur fracture in children
- It is wedge shaped, base of triangular fragment indicating the site of impact and apex pointing the direction of vehicle.
- Bumper injuries are at different level of the two legs or absent on one leg, it means the victim was walking or running when struck.
- If bumper injuries are at the same level on both legs, it means the person is standing.
- Level of bumper injury (height of injury from the ground) varies with height of bumper of different vehicle, so the offending vehicle can be identified.



Secondary impact injuries

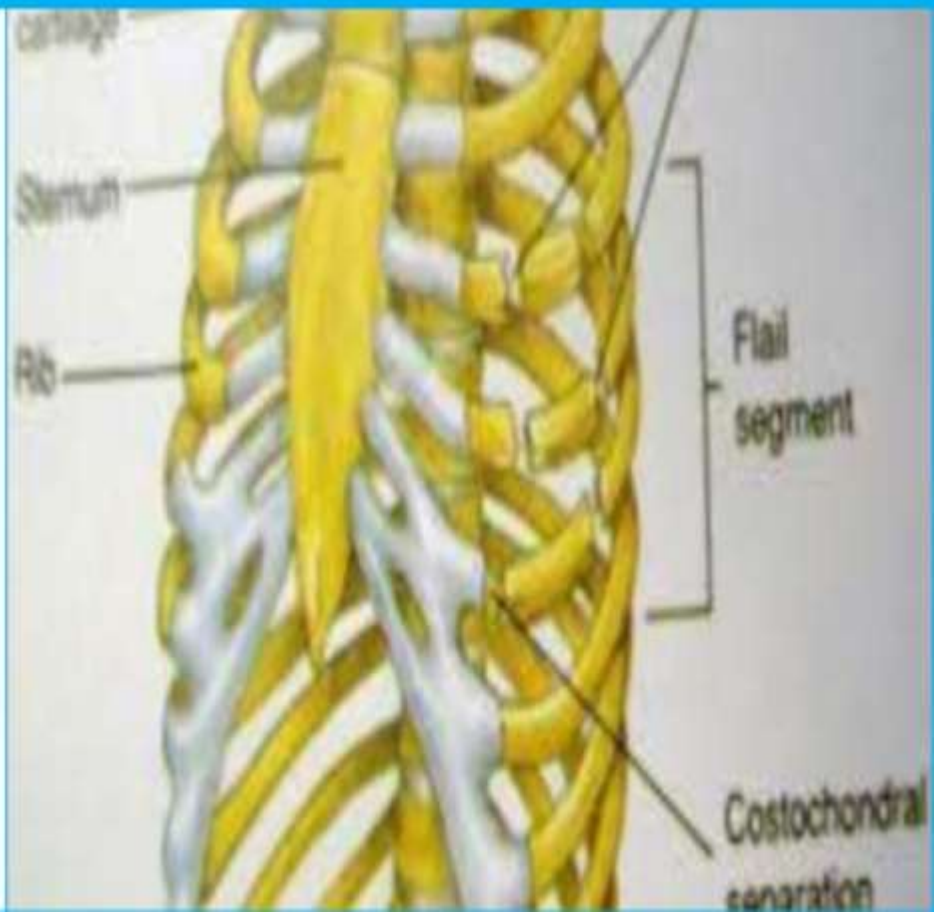
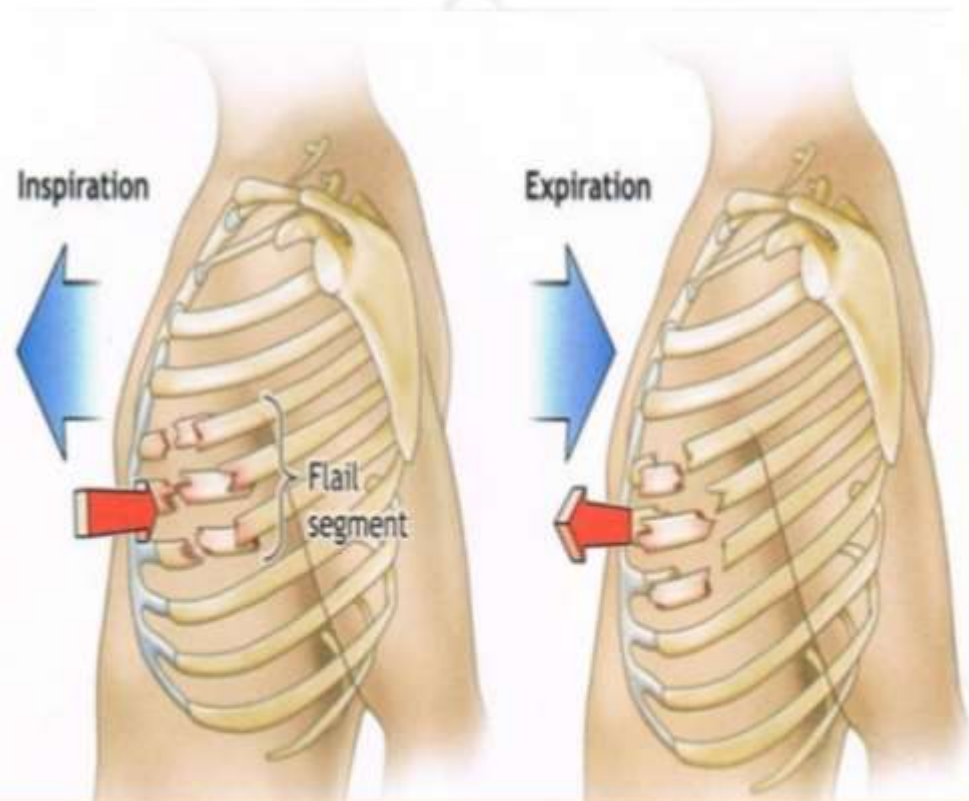
- It is due to the impact of victim with the vehicle for a second time.
- Victim strikes to windshield or bonnet or placed on the top of car.
- It is found on the opposite side to primary impact over the unclothed areas of the body.
- Extensive abrasions, bruises and lacerations .
- Burning, singeing of skin and hair by hot exhaust discharge.



Flail Chest

Chest compression causes multiple rib fractures and a “flail chest” with rupture of internal organs along with the fracture of spine, sternum and ribs.

Flail Chest:-



Run-over Injuries

- Vehicle runs over pedestrian if his gravity center is lower than the impact side.
- Severity of injury (variability) depends on the part of body run over and weight of the vehicle
- Tyre marks, abrasions, lacerations , skin burn, rupture of internal organs and avulsion.
- Tyre marks are over the unclothed or clothed areas of body with graze like abrasions on the opposite side of body.
- Gross distortion and externalization of the brain may occur due to the crushed head.
- Severe chest, pelvis and abdomen injuries may occur .

Secondary Injuries

- It is after second impact injuries where victim is lifted off the ground and thrown off the vehicle on the ground.
- Brain injury may occur without skull fractures.
- Skull and ribs fracture may occur
- Spine fracture is due to hyperflexion or extension .
- Limbs fracture are common but apart from toes of the legs.
- Victim may be run over by the same vehicle or another vehicle.
- It is very difficult to identify the injuries as primary or secondary impact or secondary injuries.
- Common cause of death is head injuries and fracture dislocation of cervical spine in pedestrian accidents.
- Injuries to the chest and abdomen are minimal.

Occupants of vehicle

Injuries by occupant of a vehicle:

- Driver.
- Ejection of driver and passenger
- Door burst open.
- Unbelted rear seat occupants.
- Tissue injury is caused by a change in the rate of movement.
- The change of rate is traumatic (acceleration or deceleration).
- A constant rapid speed has no effect.

The Driver and Passenger Injuries

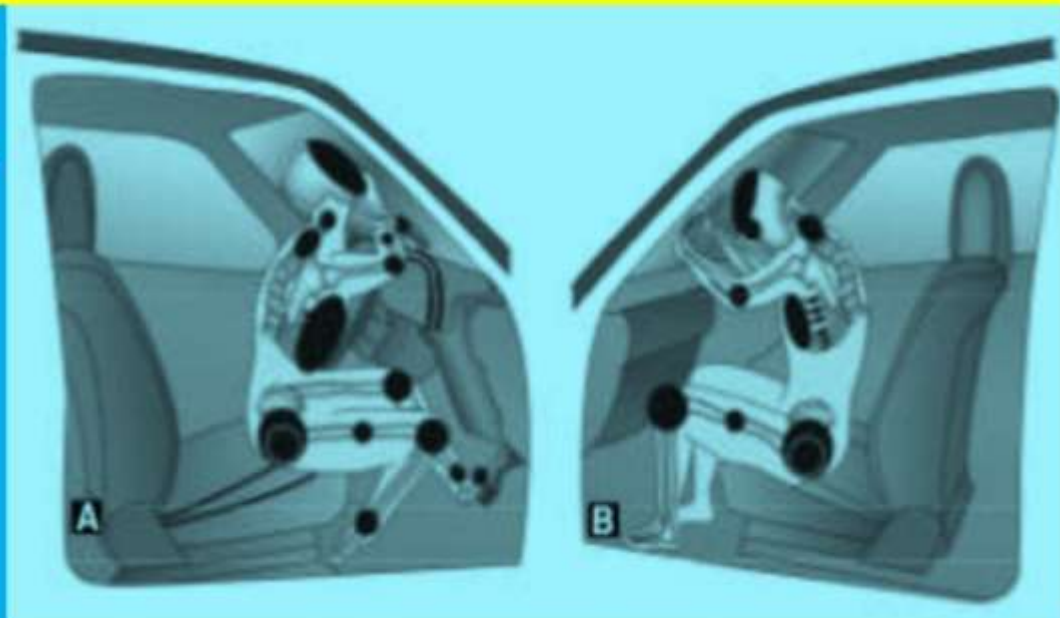
Front impact crash

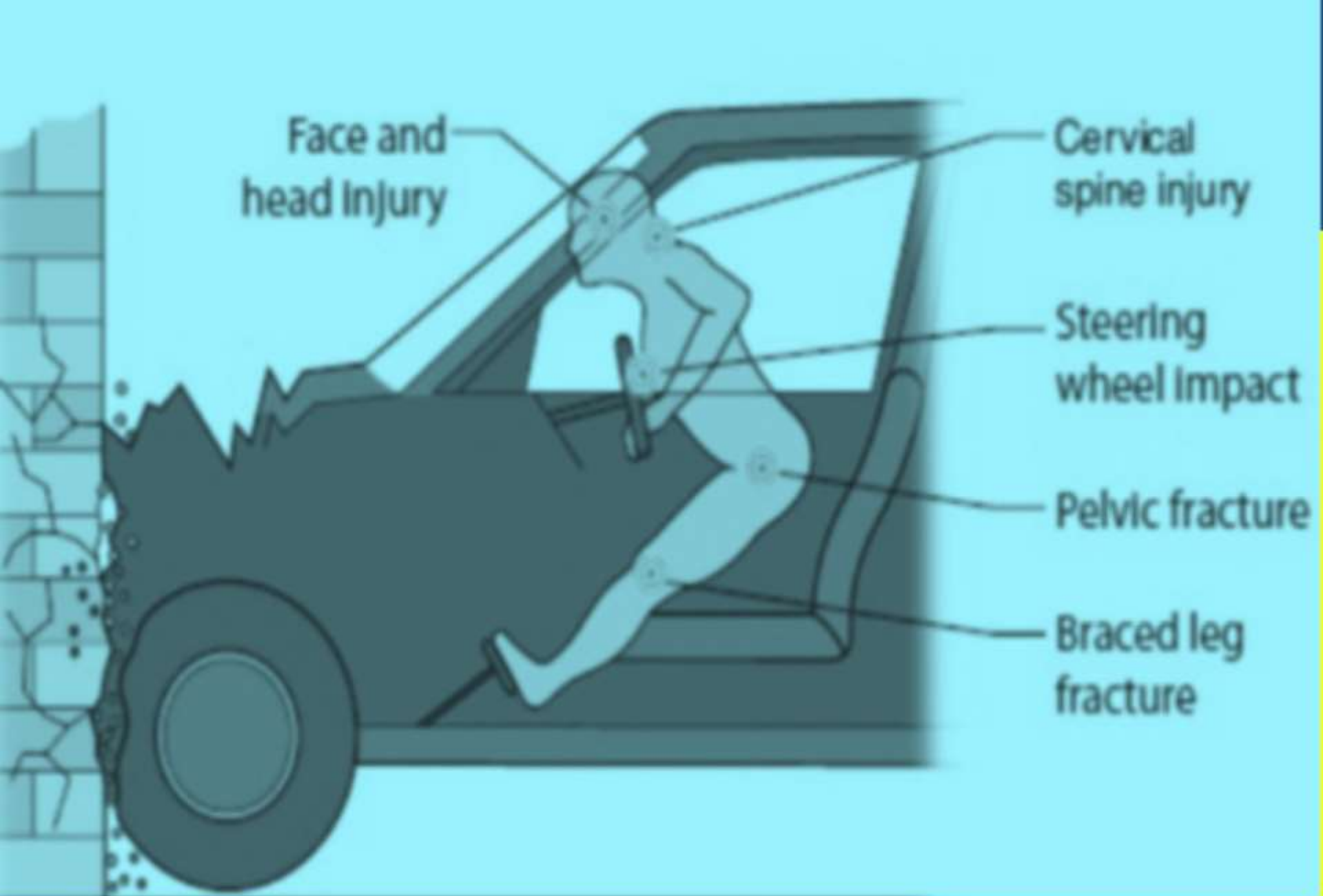
one car strikes another car or stationary object like an electric pole or tree.

Unrestrained Driver

First, he slides forwards → his legs strike the shelf area and his abdomen or lower chest contacts the lower edge of the steering wheel → the body then flexes across the steering wheel and begins to rise → the heavy head goes forwards → flexion of cervical and thoracic spines.

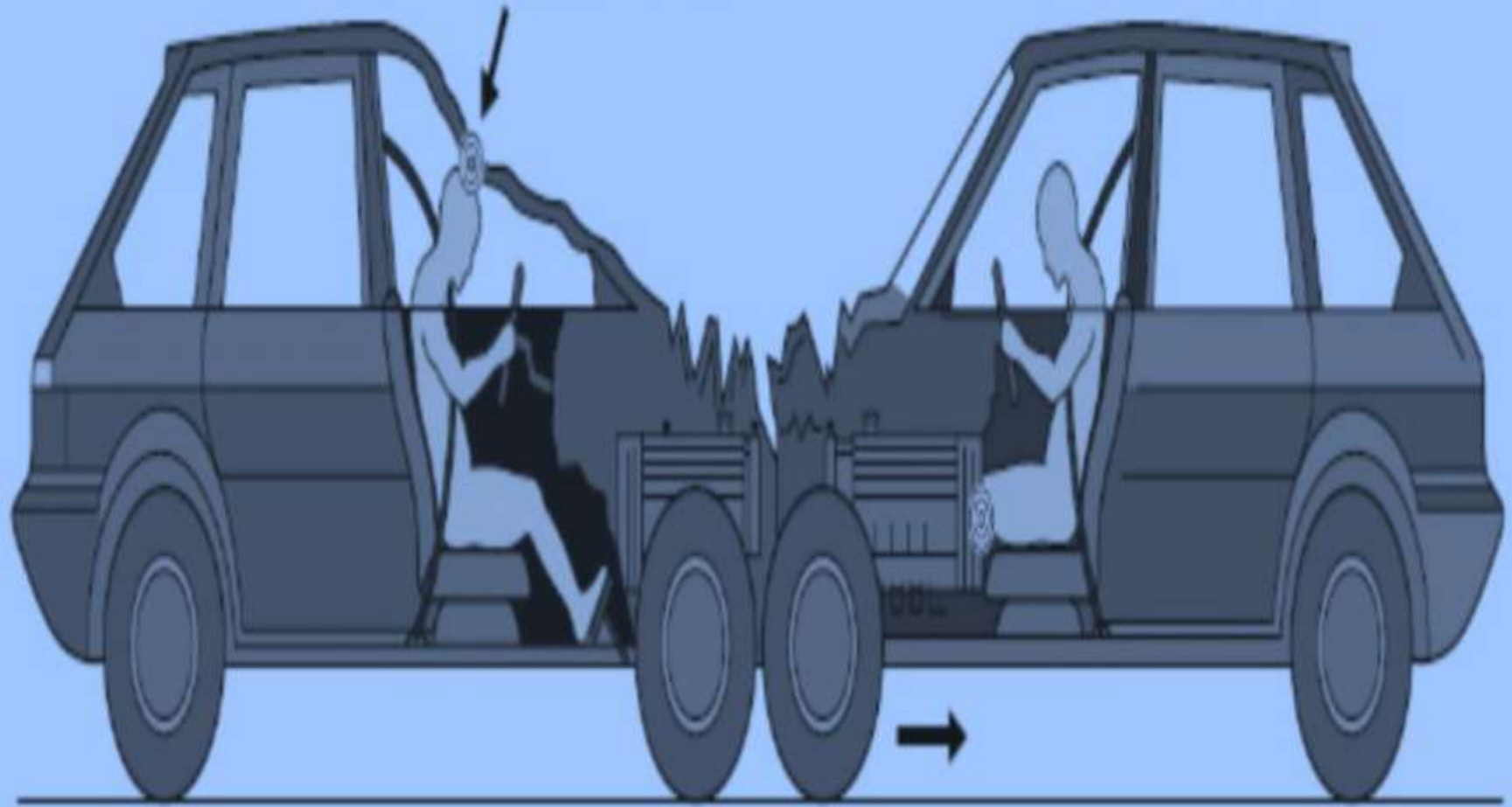
- Upward and forward movement cause the head to strike the windscreen (the upper windscreen rim or the side pillar).





Injury of Unrestrained Driver

Intrusion of
roof or 'A'-frame



Intrusion of engine
and front suspension

- Windscreen is perforated by the head or face and the whole body may be ejected through the broken glass to land on the bonnet or even on the roadway.
- The intrusion of structural parts into the passenger compartment.
- The engine or front-wheel assembly is forced back into the seating area of the driver.
- The roof or front corner pillar (frame) may fall on top of the driver.
- The steering column forced back to crush the driver's chest or abdomen.
- Column, engine, or gearbox intrusion force backwards against the driver's feet and legs.
- Pedals cause impact with legs and the pelvic girdle.
- Door may burst open and the unrestrained driver ejects sideways onto the road especially in a roll-over crash.

Severe impact against the windshield pillar:

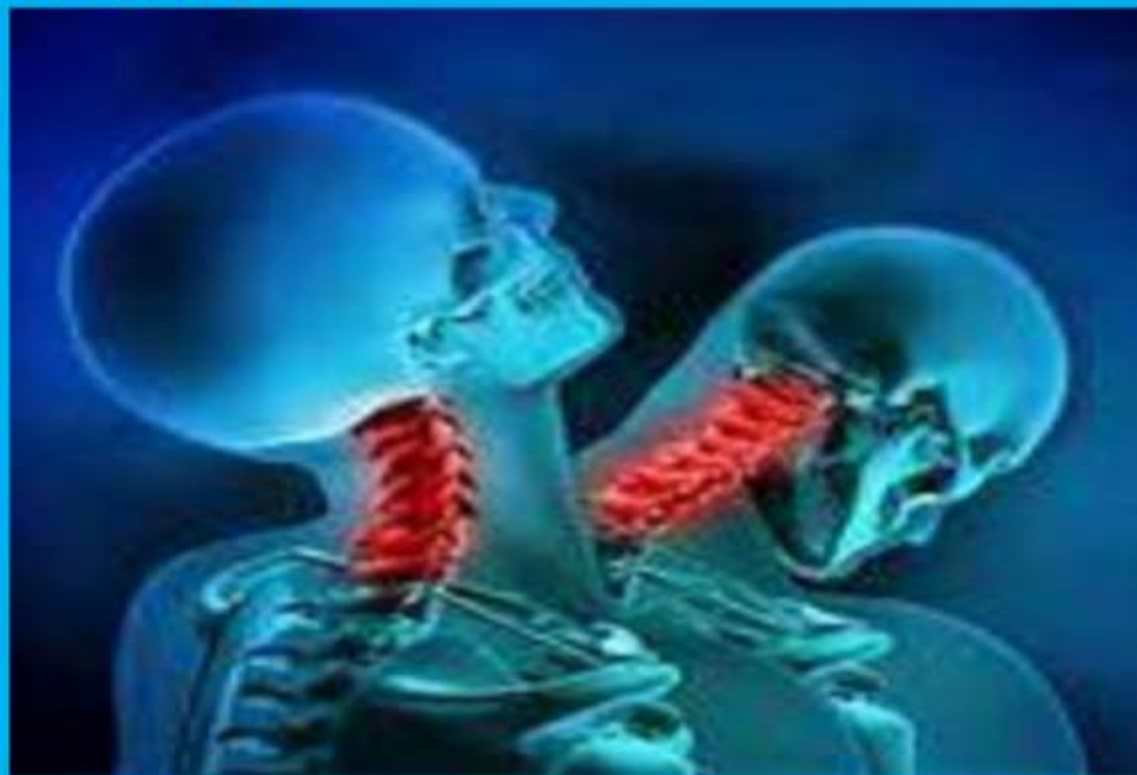1. Avulsion of the skin of forehead.
2. Basilar skull fractures.
3. Closed head injury.
4. Fracture or dislocation of spine.

Steering wheel impact injury:

1. Jaw fracture.
2. Facial bones injury.
3. Abrasions, bruises, contusions of chest.
4. Bilateral rib fracture.
5. Lacerations of spleen and liver.

Front Seat Passenger

1. Whiplash injury
2. Sparrow foot marks
3. Injured against doors, handles or ejected through burst-open doors.



Whiplash injury



Side impact crash



- Vehicle strikes side of another vehicle or fixed object.
- Side of car has thin metal wall door that can not absorb the force of impact, so Injuries are severe.
- They are linear, right angel or V- shaped laceration on the face and arms .
- Dicing injuries are superficial cuts of skin caused by glass fragments.
- Lateral right impact causes lacerated right lobe of liver , lung and kidney.
- Fracture pelvis is from the either side impact.
- Fracture of cervical spine and ribs, contusions and lacerations.

Rear impact

- Driver is violently accelerated → If head restraint is not fitted to the seat → deceleration sequence occurs when the car is obstructed in front → severe hyperextension of the neck → causing whiplash.
- Low velocity rear impact causes whiplash injury and neck fracture is rare.
- High velocity rear impact ruptures the gas tank and ignition of the fuel.

The driver has

- Fracture of wrist and arm because of steering wheel impact.
- Fracture or dislocation of tibia, fibula, femur, pelvis

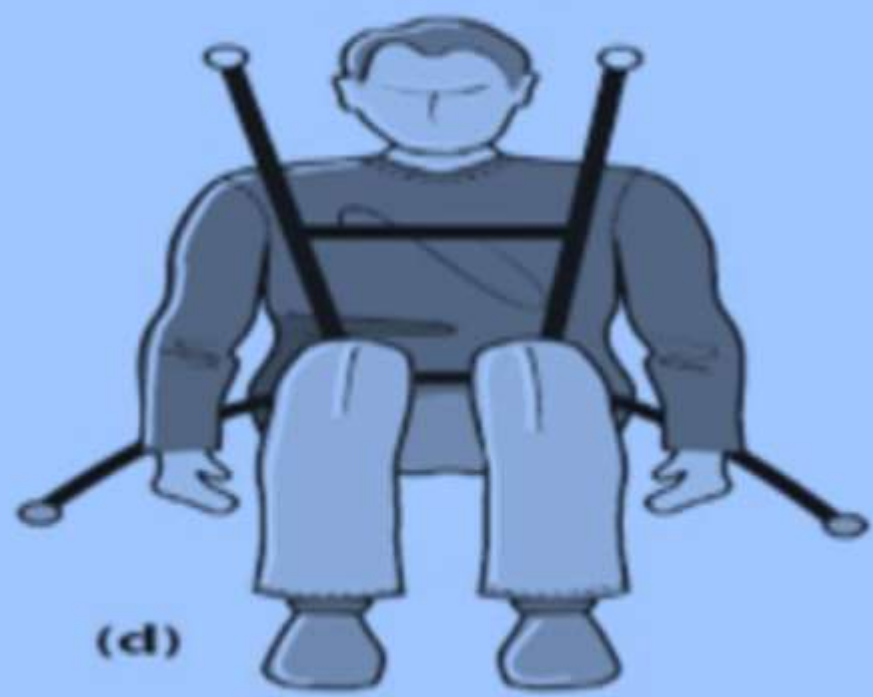Roll - over crash

- The occupants receive moderate impact, if the vehicle has not a sudden stop.
- The crashing of different sides of vehicle absorb the impact force .
- If the passenger compartment remain intact, the belted occupants survive.
- Non belted occupants are involved into two types of injury: -
 - 1-Tumbling around inside and striking.
 - 2- Ejection out of the vehicle.

Safety Features



- Seat belt and air bag, collapsible steering column, Softened interior dashboard and anti lock break.
- Air bag reduces chest and facial trauma.
- Seat belt reduces the fatalities to front seat occupants by 45% because injuries are less severity, except whiplash injury.
- Severe head injury and ejection from the vehicle is lower, fewer fatal injuries to neck, chest and abdomen.
- Lap belts produce tears of mesentery, omentum and laceration of bowel .
- Shoulder belt produce a linear abrasion running downward and medially on the right side of driver and left side of front seat passenger.
- Seat belt reduces mortality, but it causes specific pattern of internal injuries.



Determine

- 1- Cause of accident (criminal)
- 2- Cause of death
- 3- Accident reconstruction

Identify

- 1- Victim
- 2- injuries
- 3- Scene of accident



Role of Forensic Expert

**How to investigate the road
traffic accident by forensic
expert**



Scene

Road marks, Blood
(size and direction) and
Broken car parts

Vehicle

Speed, Direction
and Type & Extent
of damage

Investigation of traffic accident

Victim

Position, Distance
Clothes and Body
injuries, Drag mark

Cause of death

Traumatic injuries
Trauma and natural
disease

Cause of accident

Natural disease, Drug and alcohol,
Suicide & Psychic factors and
Highway cause

Motorcycle & Cycle Injuries

Injuries are much more serious because:

- Inherent instability of two wheeler.
- Unprotected and lack of protective gear.
- Rush and negligent driving .

The common causes of motorcycle accidents:

Alcohol, drugs, environmental factors, reckless driving and failure by the drivers of cars to see the motorcycle.

The most common cause of motorcycle fatality is running off road.

Common injuries of motorcycle accident

- Most injuries are due to ejection from the vehicle into the roads or due to high speed and instability of the vehicle.
 - **Primary injuries** are open fracture of the tibia and fibula.
 - **Secondary injuries** are fracture of the skull, ribs and cervical spine as well as contusions of brain.
- There are graze abrasions due to sliding across the road.

Motorcycle accident injuries

- Regions are more affected : head, thoracic and abdominal regions.

Skull fracture of motorcyclist can be :

- Fall on road surface (lateral part “temporo- parietal fracture”)

- Fall on side with side impact to head causes basal skull fracture especially hinge type .

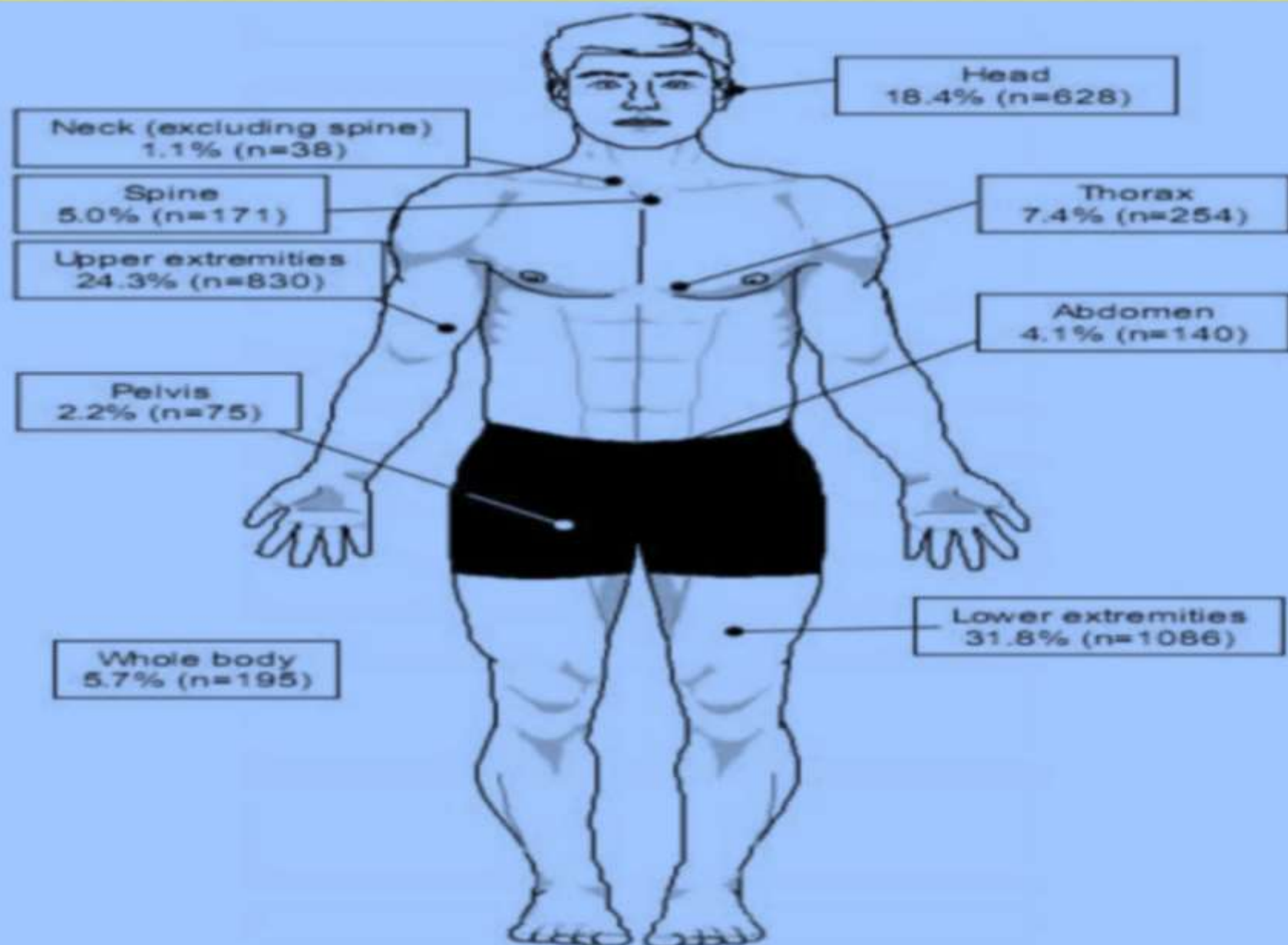
- Impact on face causes facial skeleton fracture.

- Impact on forehead causes sagittal fracture of skull base .

- Impact on chin causes mandibular fracture.

- Impact on crown of the head causes ring fracture.

Risk areas



Thank you