

Common Neck Injuries

Presented

By

Dr. Said Said Elshama

Professor of Forensic Medicine and Clinical Toxicology

Medical Education (DHPE)

College of Medicine - Taif & Suez Canal University

Types of neck injuries :-

1- Cut throat

A-Suicidal Cut throat

B- Homicidal Cut throat

2- Abrasions and Bruises

A- Throttling

B- Strangulation

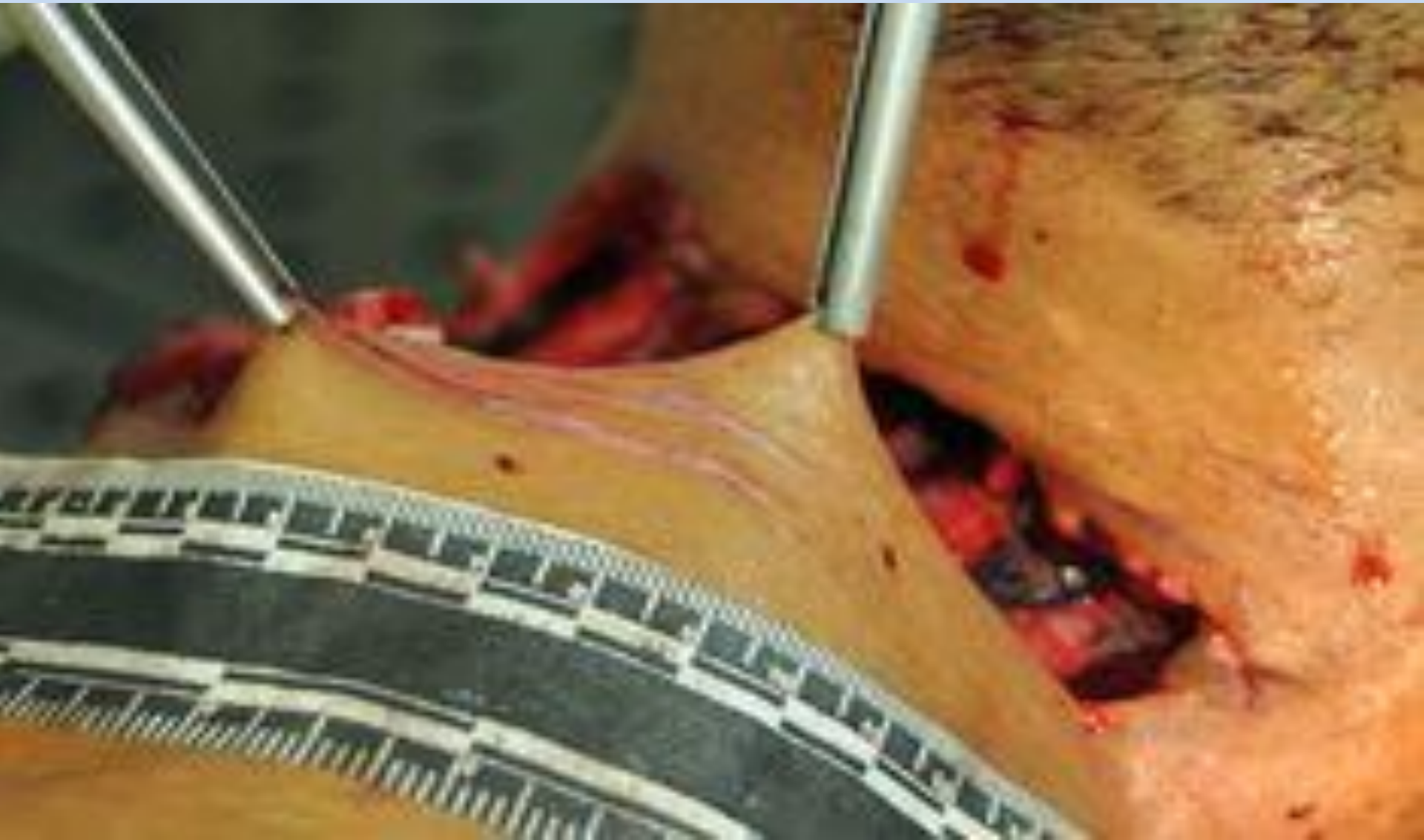C- Hanging

1- Cut (Cut throat) wound :-

A- Suicidal Cut throat

- It is oblique direction and high above thyroid cartilage .
- Hesitation marks in the left angle of mandible (right handed).
- Deep cutting on the left tailing superficially to the right (right handed).
- Skin is cutting at a higher level than the deep tissues.
- No signs of struggle.
- Circumstantial evidence.

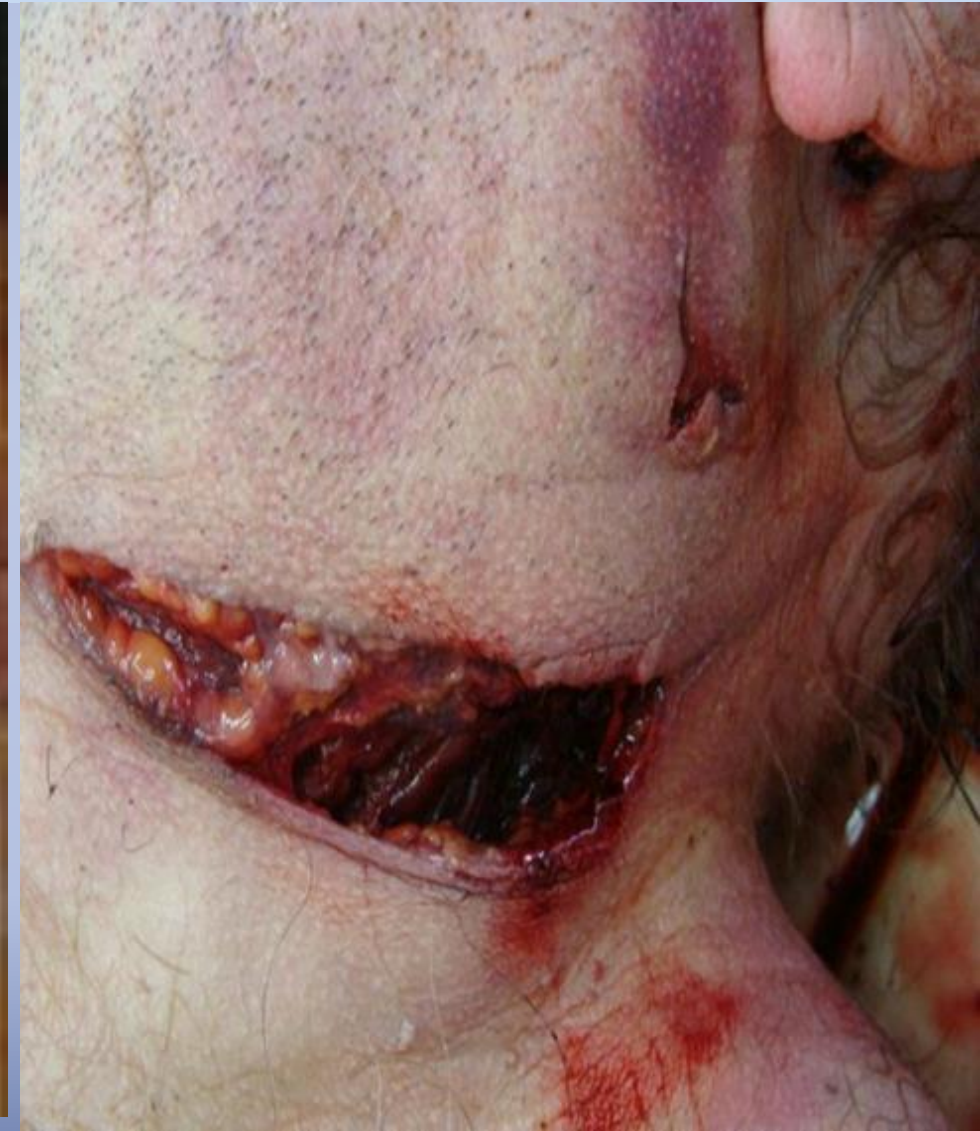Suicidal Cut throat (hesitation marks)



B- Homicidal Cut throat

- It is low and below the thyroid cartilage
- Direction of wound is horizontal.
- Deep cutting from the starting point to the end point.
- Equal on either side of the neck.
- It may surround the neck.
- Skin and the deep tissues are cutting at the same level .
- Presence of multiple cut wounds in the neck .
- No Hesitation marks.
- Signs of struggle .
- Circumstantial evidence.

Homicidal Cut throat



Causes of death in Cut throat

- 1- Neurogenic shock (cardiac vagal inhibition).**
- 2- Hemorrhage .**
- 3- Venous embolism.**
- 4- Delayed causes :-**
 - edema in glottis**
 - aspiration pneumonia**
 - infection**

2- Abrasions and Bruises

A- Throttling (manual strangulation)

B- Strangulation

C- Hanging

❖ General external and internal signs of asphyxia are associated with throttling , strangulation and hanging.

Signs of asphyxia

External

Dark blue hypostasis

Deep cyanosis

Bulging eyes

Sub-conjunctival Hge.

Protruded tongue

Bloody froth

Internal

Congestion of mucous membranes of air passages

Congestion of viscera

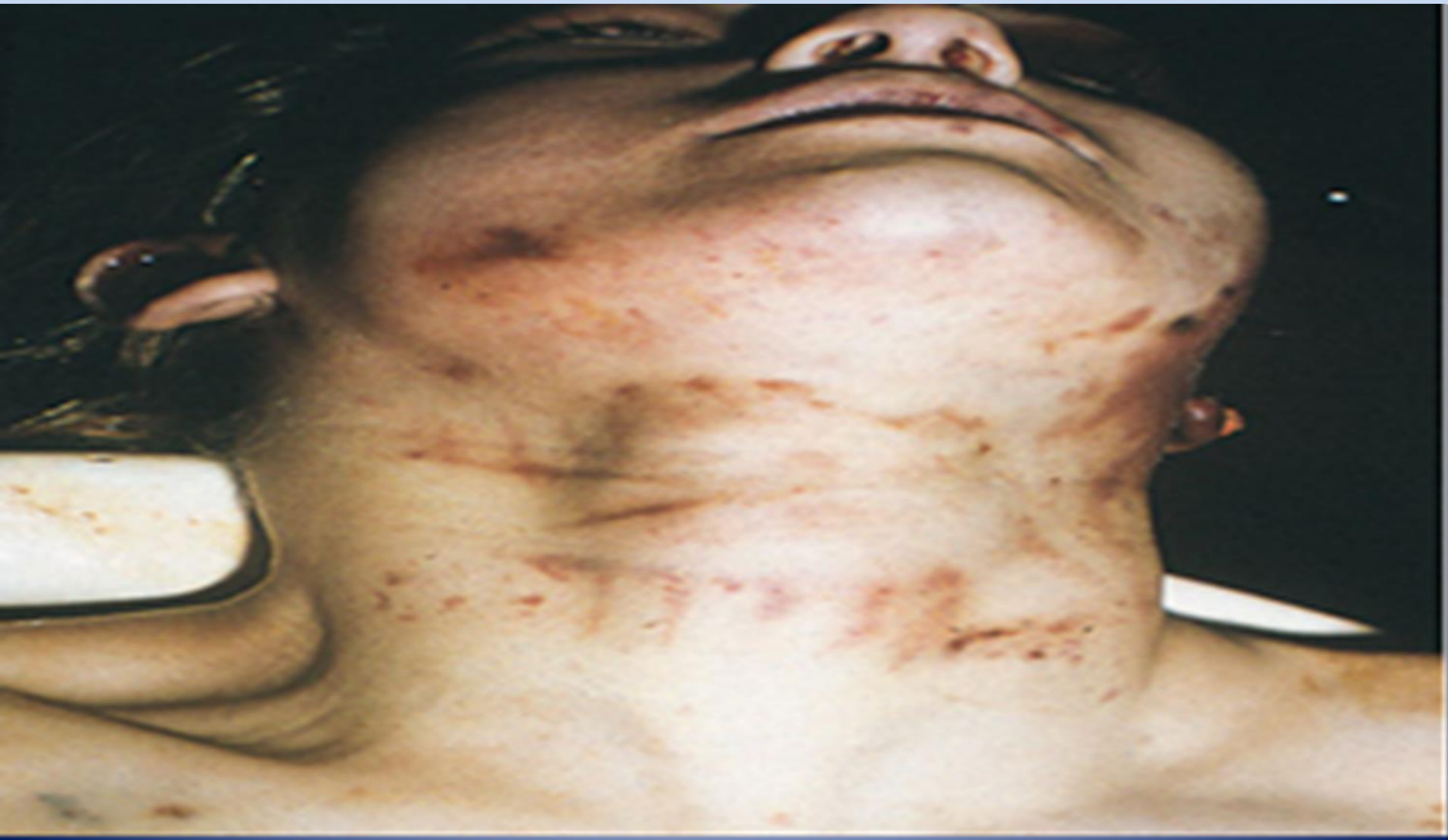Dark fluid blood

Sub-pleural petechial hge and silvery spots

A- Throttling (manual strangulation)

- **Asphyxia due to hands pressure on the neck.**
- **Asphyxia due to airways occlusion leading to the death.**
- **Pressure on carotid sinus leading to syncope as a result of vagal inhibition reflex leading to the death.**
- **Semilunar nail abrasions and bruises on neck**
- **Bruises of larynx, trachea , supra and infra- hyoid muscles**
- **Fracture of hyoid bone (displaced inward fracture of cornu)**

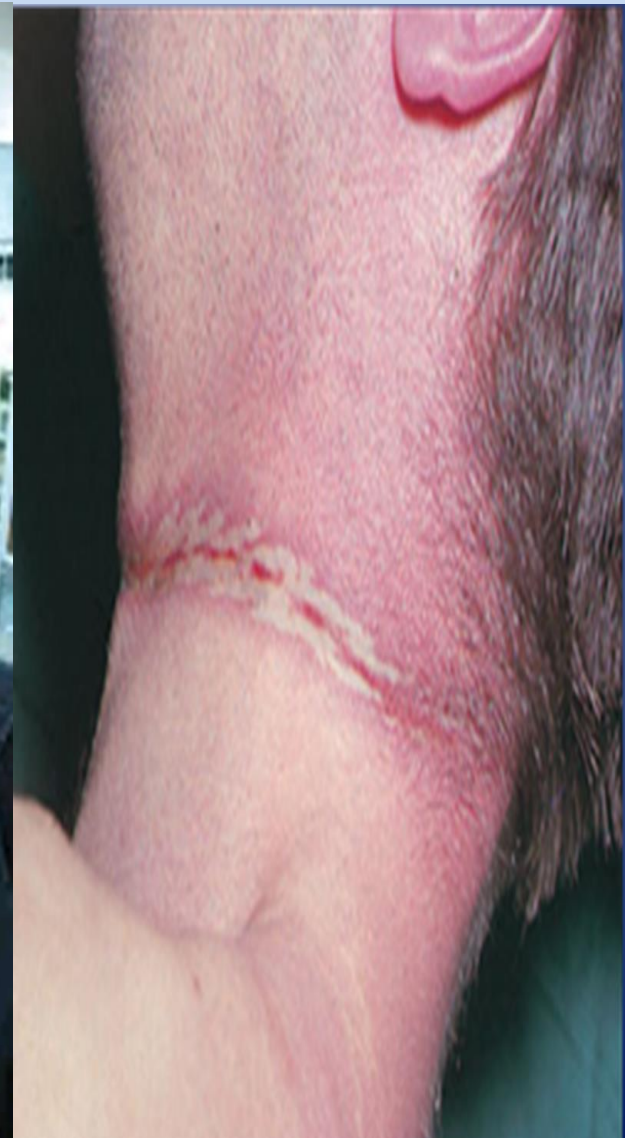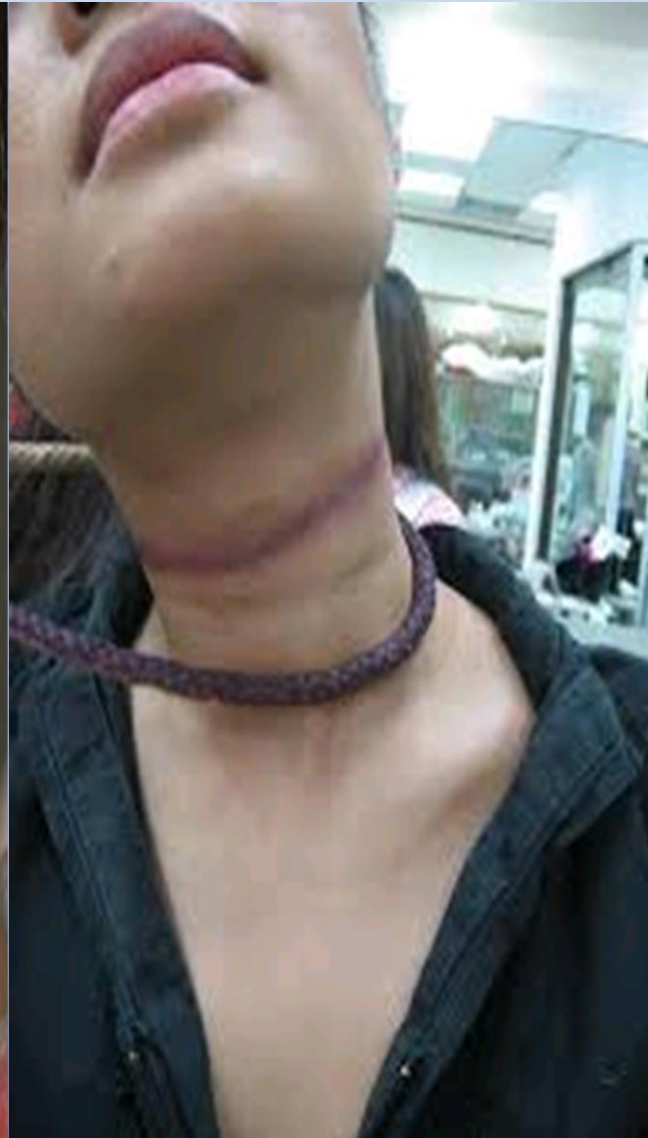
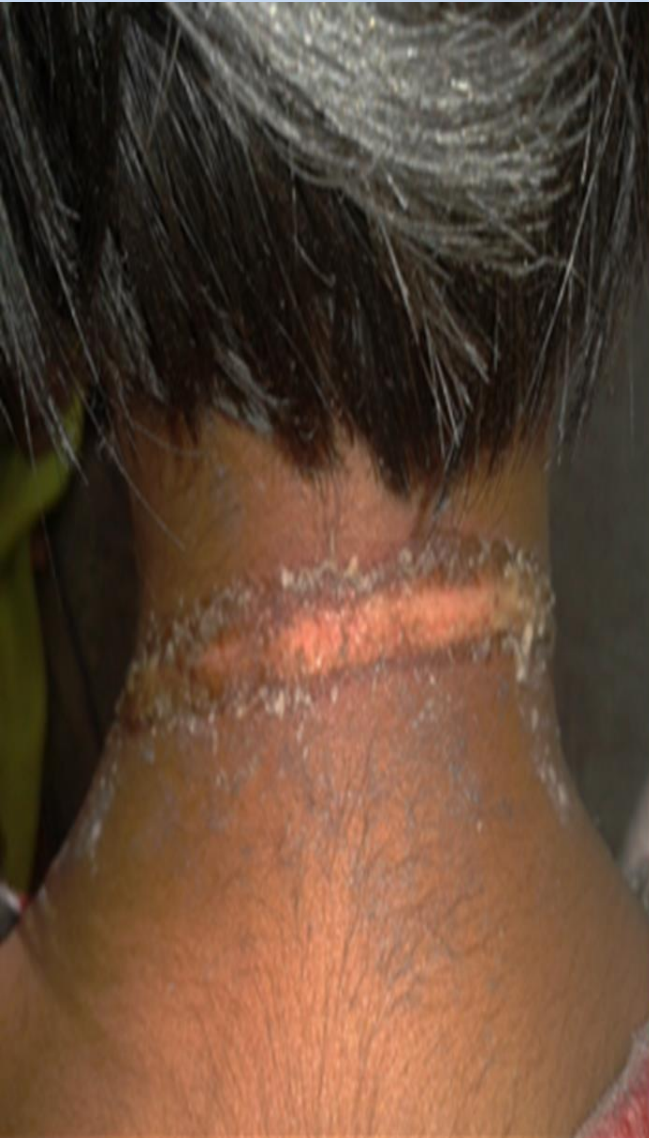Bruises in Throttling



B- Strangulation

- Asphyxia due to ligature pressure on the neck.
- Asphyxia due to airways occlusion leading to the death.
- Ligature mark (circular abrasion around the neck)
- The rope mark is transverse, symmetrical, complete and below the larynx.
- Bruises and congestion with lacerations of supra and infra- hyoid muscles and larynx.
- Fracture of hyoid bone and laryngeal cartilage

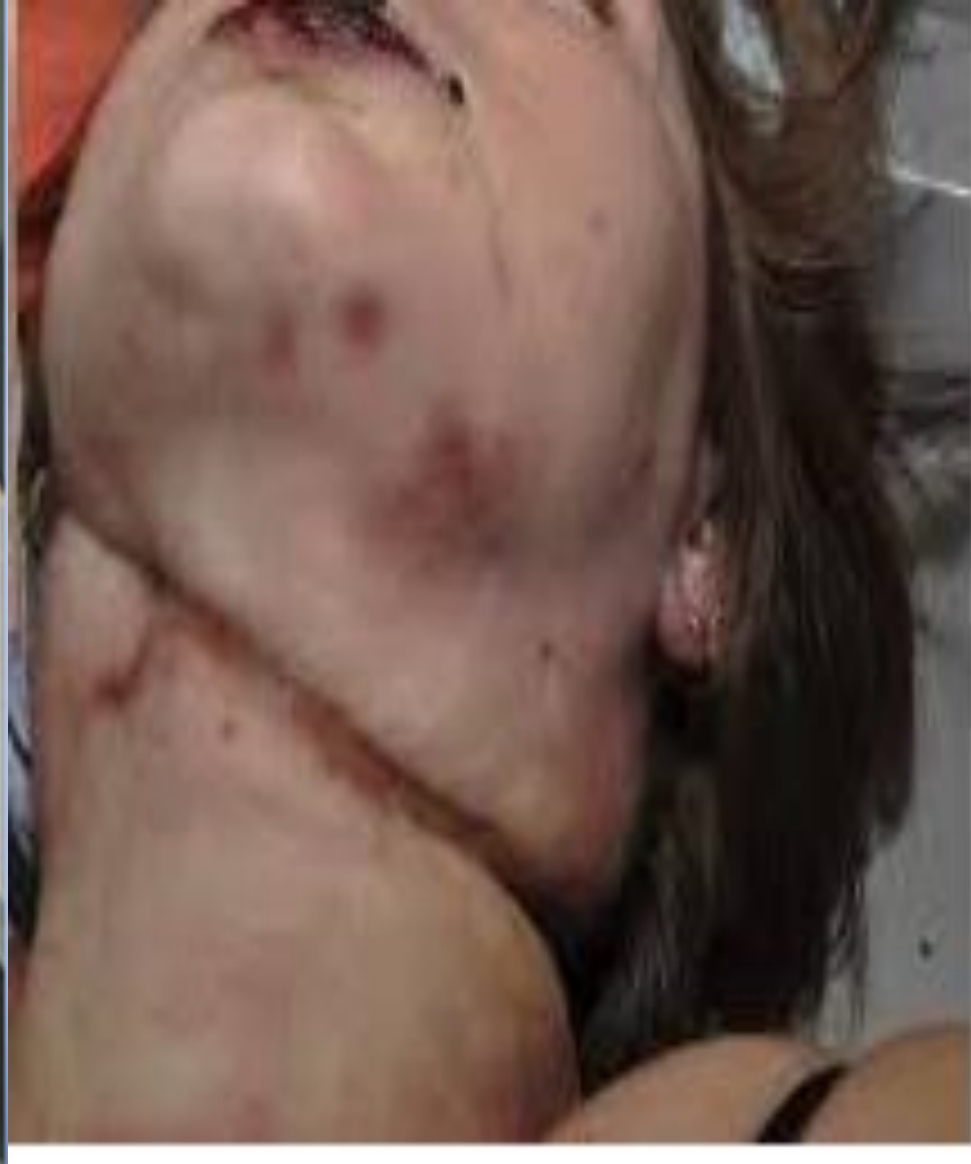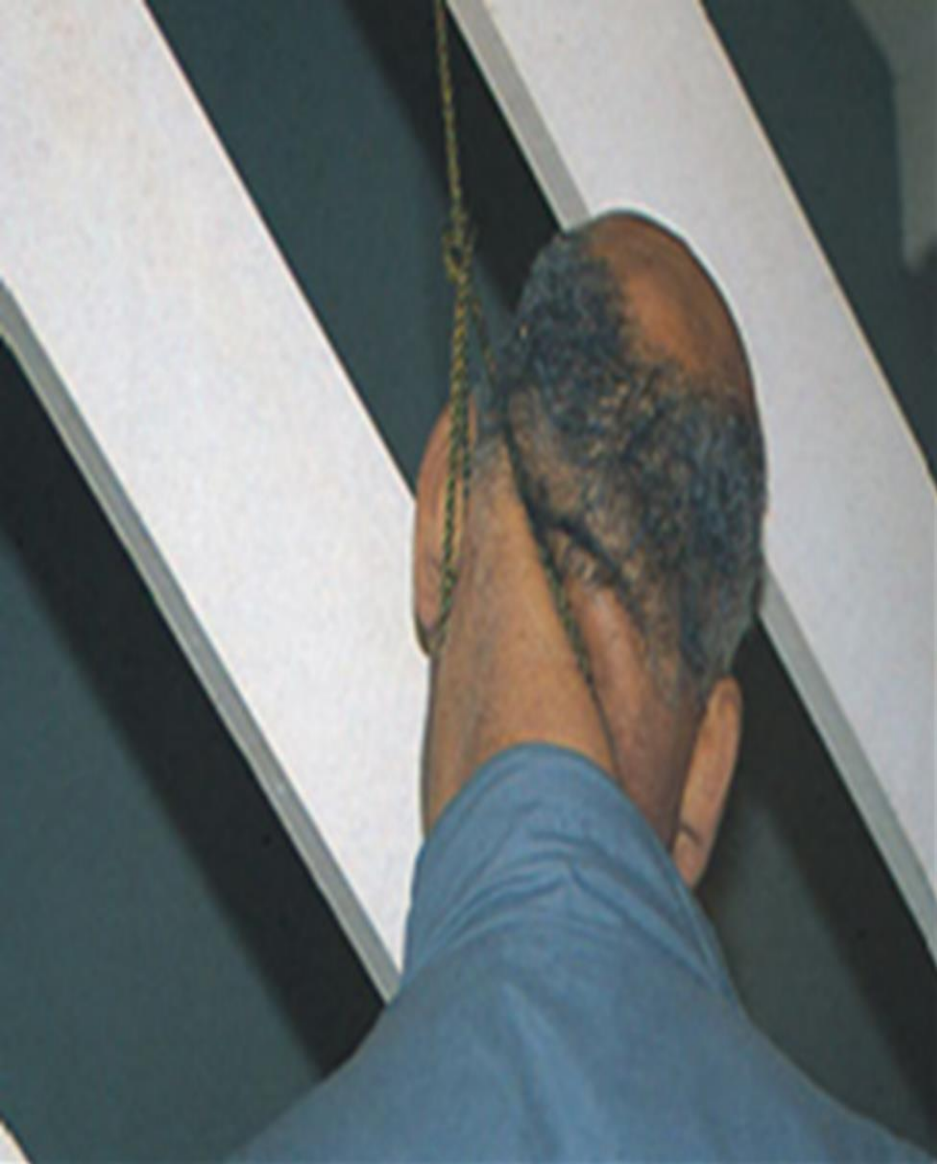Rope mark of strangulation



C- Hanging

- Suspension of the body from the neck by a ligature (Slip- knot).
- Ligature mark is oblique, incomplete, constriction abrasion and above the larynx.
- The mark is deepest opposite the suspension point.
- Fracture of hyoid bone (outward fracture).
- Carotid arteries injury with dribbling of saliva.
- Death is due to airways obstruction ,cerebral ischemia, reflex cardiac inhibition, fracture and dislocation of cervical vertebra.

Rope mark of hanging



Thank you